

Protective effects of hydroalcoholic extract of *Coronilla securidaca* L. seeds on serum levels of plasma blood parameters, antioxidant status and liver tissue changes in tamsulosin treated rats

Sedigheh Khezri Motlagh, Mokhtar Mokhtari* & Mehrdad Shariati

Department of Biology, Islamic Azad University, Kazerun Branch, Kazerun, Iran

Received 08 July 2022; revised 04 August 2023

The seeds of Goat pea or Hatchet vetch [*Coronilla securidaca* L. syn. *Securigera securidaca* (L.) Degen & Dörfel.] are rich in phenolic compounds and have many biological activities. Here, we tried to evaluate the protective effects of hydroalcoholic extract of *C. securidaca* seeds (HECS) on serum levels of blood plasma parameters, antioxidant status and liver tissue changes in tamsulosin (TAM) treated rats. Rats were divided in 9 groups of 8 each including control, sham, TAM0.4, HECS200, HECS400, HECS800, TAM0.4 + HECS200, TAM0.4 + HECS400 and TAM0.4 + HECS800. HECS and TAM were administered orally for 28 days. At the end of the study, to investigate the changes in blood plasma parameters and antioxidant status, serum levels of glucose, alanine transaminase (ALT), aspartate transaminase (AST), alkaline phosphatase (ALP), albumin (Alb), total protein (TP), total bilirubin (TB), catalase (CAT), glutathione peroxidase (GPX) and superoxide dismutase (SOD) were measured. TAM0.4 administration significantly increased serum levels of glucose, ALT, AST, ALP and TB ($P < 0.05$), in contrast, it significantly decreased serum levels of Alb, TP, CAT, GPX and SOD ($P < 0.05$). TAM0.4 + HECS800 administration decreased serum levels of glucose, ALT, ASP, ALP and TB ($P < 0.05$), in contrast, it increased serum levels of Alb, TP, CAT, GPX and SOD ($P < 0.05$). Liver tissue degradation and necrosis were observed in TAM0.4 but a relative improvement of liver tissue and mild necrosis was observed in TAM0.4 + HECS800. HECS administration at a dose of 800 mg/kg, can create protective effects on liver tissue by improving biochemical parameters, antioxidant status and prevent liver tissue destruction in TAM treated rats.

Keywords: Alpha blockers, Antioxidants, Goat pea, Hatchet vetch, Hepatic transaminases, Liver, Tamsulosin

Currently, alpha blockers are used to treat benign prostatic hyperplasia (BPH). These drugs exert their effects by binding to alpha receptors and relaxing smooth muscles which reduce the symptoms and disorders of the urinary system¹. There are five types of alpha blockers, including tamsulosin, doxazosin, silodosin, terazosin and alfuzosin, that have general applications. Alpha blockers (such as tamsulosin) have no direct anti-inflammatory effects and have potential side effects on the function of various tissues in the body²⁻⁴. Tamsulosin (TAM) is an α_1 -adrenergic receptor antagonist specifically prescribed for the treatment of BPH, because the urinary tract is highly selective for α_1A -adrenergic receptors⁵. This drug causes fewer side effects than other α -blockers⁴.

Liver which metabolizes many drugs and chemicals, often suffer from hepatotoxicity caused by various drugs with different mechanisms. This is

because almost every drug treatment has the potential for hepatotoxicity⁶. It has been reported that acute hepatitis can be caused by adrenergic receptor antagonists. Earlier studies have demonstrated TAM induced hepatotoxicity^{2,7}. Tamsulosin exerts its toxic effects by causing oxidative stress in target tissues. Administration of TAM in rats has been shown to be associated with decreased serum levels of catalase (CAT), superoxide dismutase (SOD), glutathione-S transferase (GST), ascorbic acid and glutathione⁸. Contrary to these results, it has been shown that tamsulosin can reduce the damage caused by oxidative stress by reducing inflammatory factors⁹.

Today, finding a way to manage diseases and chemical drugs using natural remedies is rising. Polyphenols are the most abundant natural antioxidants and are common compounds in many plant sources^{10,11}. However, studies conducted on the role of polyphenols in the management of drugs such as tamsulosin are few¹². *Coronilla securidaca* (CS), commonly known as Hatchet Vetch or Goat pea, is an annual plant belonging to the Fabaceae family found

*Correspondence:

Phone: +98 9171811963 (Mob.)

E-Mail: m.mokhtari246@yahoo.com

wildly in Europe, Africa and West Asia. This plant is used in a variety of disorders such as diabetes, hypertension, hyperlipidemia, and epilepsy in traditional medicine^{11,13}. Photochemical decomposition of hydroalcoholic extract of *Coronilla securidaca* (HECS) confirms the presence of alkaloids, flavonoids, phenols, saponins and tannin¹⁴. Many studies have reported the antihyperglycemic and antioxidant properties of the HECS seeds. Bioactive compounds found in CS seeds are mostly fatty acids, which show antidiabetic and antioxidative properties^{11,13,14}. Therefore, in this study, we tried to investigate the effects of hydroalcoholic extract of *Coronilla securidaca* (HECS) and tamsulosin (TAM) separately and in combination on the levels of blood biochemical parameters, antioxidant status and liver tissue changes in rats.

Materials and Methods

Animals

Male Wistar rats were used in this experimental. The animals were purchased from the Animal House of the Islamic Azad University, Kazerun Branch and kept in the same place. Before starting the study and to adapt the animals to each other, all animals were exposed to 12 h of light/darkness, controlled temperature of 22±1°C and 50-60% moisture for two weeks. This condition was maintained until the end of the study. In all stages of the study, the ethical and practical principles of working with laboratory animals were observed (code number of ethics: IR.IAU.KAU.REC.1400.195). In each cage, 4 rats were kept and had free access to adequate water and food. The food of the animals was in the form of pellets (Daniran, Iran).

Study protocol

Seventy-two adult, male Wistar rats weighing 200-220 g and the age range of 2.5-3 months were randomly grouped into 9 groups of 8 rats each. The animals in the control group (Gr. I) did not receive drug treatment for 28 days. In the sham group (Gr. II), the animals received only 1 mL of distilled water as the drug solvent orally for 28 days. Animals in the TAM0.4 group (Gr. III) received 0.4 mg/kg tamsulosin orally every day at 9 AM for 28 days. In the HECS200 (Gr. IV), HECS 400 (Gr. V) and HECS 800 group (Gr. VI), the animals received 200, 400 and 800 mg/kg of HECS orally every day at 5 PM for 28 days, respectively. Similarly, animals in the TAM0.4 + HECS200 (Gr. VII), TAM0.4 + HECS400

(Gr. VIII), and TAM0.4 + HECS800 group (Gr. IX) received 0.4 mg/kg tamsulosin daily at 9 AM and 200, 400 and 800 mg/kg of HECS orally at 5 PM for 28 days, respectively. Doses of HECS and tamsulosin were determined and prescribed based on the previous studies^{11,14,15}. At the end of the study, blood samples were taken from all the animals and body weight, liver weight, serum levels of glucose, alanine transaminase (ALT), aspartate transaminase (AST), alkaline phosphatase (ALP), albumin (Alb), total protein (TP), total bilirubin (TB), catalase (CAT), glutathione peroxidase (GPX) and superoxide dismutase (SOD) were measured.

Preparation of HECS

The seeds of CS (*Coronilla securidaca* L.) were purchased and then, the genus and species of the plant were identified and approved by the Botany department of the Islamic Azad University, Kazerun branch. The seeds were washed with sterile water and after drying, they powdered and sieved with an electric mill at room temperature (24°C). The resulting powder was mixed with 70% ethanol solvent (Merck, Germany) in a ratio of 1:10 by weight. The sample was placed semi-continuously for 30 min at a frequency of 50 Hz at 30°C in the ultrasonic machine. It was then placed on a hot plate at 300 rpm for 24 h and then filtered through filter paper. Then it was concentrated for 40 min to remove the solvent and achieve the extracts by rotary evaporator at 40°C and after drying under the hood, it was kept in a closed container and air-impermeable at 4°C.

Tamsulosin (TAM)

TAM (Arya Pharmaceutical Co., Iran) was prepared in the form of tablets and distilled water was used as its solvent. Given that LD₅₀ TAM has been reported as 650 mg/kg in rats¹⁶, the dose of 0.4 mg/kg was selected¹⁵.

Determination serum levels of Glucose, ALT, AST, ALP, Alb, TP and TB

At the end of the experimental, the animals were anesthetized with ether (Merck, Germany) and their chests were cut open and 5 mL blood samples was taken from their left heart ventricle using a 5 mL syringe. Blood samples were kept at room temperature for 30 min to complete the coagulation process and then centrifuged at 3000 rpm for 5 min to separate serum. Serum was separated by Pasteur pipette and after identifying the information about each rat on the tubes, they were blocked by paraffin

and were kept at -20°C until the factors were analyzed. Serum glucose level was measured based on glucose oxidase method¹⁷ and according to the manufacturer's kit (Pars Azmoun, Iran). Serum levels of ALT, AST, ALP, Alb and TP were measured according to the manufacturer's instructions (Pars Azmoun Company, Iran) and using RA-1000 auto-analyzer (Technicon, USA). Serum ALT and AST levels were measured by IFCC (International Federation of Clinical Chemistry) method without adding Pyridoxal-50 phosphate and serum ALP levels were measured by PGKC (Deutsche Gesellschaft Fur Klinische Chemie) method. Based on photometric method, serum levels of TP and Alb were measured based on Biuret and BCG (Bromocresol-Green) methods, respectively¹⁸. Also, serum level of total bilirubin was measured by photometric method and using Diazo 2 and 4 di-Chloro aniline (DCA) according to the instructions of the manufacturer (Pars Azmoun, Iran).

Determination of catalase activity

The level of catalase activity was measured using Plate Reader and according to the instructions of the manufacturer (KiazistPishro Barman, Iran). To measure catalase activity, 20 μL of serum sample was poured into non-coagulation test tubes and incubated for 30 min at room temperature and then centrifuged at 1000 rpm for 10 min. The yellow serum was removed without aspiration of the leukocyte layer and kept at -80°C until the catalase level was analyzed. In this experiment, catalase has peroxidase activity in the presence of methanol and it is then stopped in the presence of its inhibitor and it produced formaldehyde reacts with Purpald to produce a purple dye that absorbs at a wavelength of 540 nm.

Determination of SOD and GPX activity

The activity level of superoxide dismutase (SOD) was measured by a calorimeter method using Plate Reader and according to the instructions of the manufacturer (KiazistPishro Barman, Iran). Forty microlitres of serum sample was poured into a test tubes containing anticoagulants and centrifuged at 1000 rpm for 10 min. The yellow serum was removed without aspiration of the leukocyte layer and kept at -80°C until the catalase level was analyzed. Serum samples were diluted 1:10 with dilution buffer 1X. The optical absorption of the each sample was measured at 570 nm.

The glutathione peroxidase (GPX) activity level was measured by calorimeter method using Plate

Reader according to the manufacturer's instructions (KiazistPishro Barman, Iran). Coupling was used in this kit along with glutathione reductase and NADPH coenzyme. Forty microlitres of serum sample was poured into test tubes containing anticoagulants and centrifuged at 1000 rpm for 10 min. The yellow serum was removed without aspiration of the leukocyte layer and kept at -80°C until the catalase level was analyzed. The optical absorption of the each sample was measured at 340 nm.

Histopathological analysis

The weight of each animal was measured and after that they were anesthetized and blood sampling done. The liver of each animal bringing out from the abdominal area and that was washed with physiological serum and weighed with a digital scale. For fixation, liver tissues were placed in Bouin solution for 2 h and gradually dehydrated with ethanol, clarification with xylene and molding with paraffin were performed. A 5-micron serial cuts were made by microtome machine and stained with hematoxylin-eosin method. After staining, microscopic slides were prepared and examined using a light microscope with a magnification of 100. Dino Capture 2 software was used to study the tissue photos.

Statistical analysis

The resulting data were analyzed using SPSS software version 20 (SPSS Inc, Chicago, IL, USA). ANOVA method and LSD test were used to compare the means of the data and the obtained values were expressed as Mean \pm SEM in the graphs and the significance level was considered $P < 0.05$. Ghraphpad 6 (GraphPad Prism, Inc., San Diego, CA, USA) was used to draw the Graph.

Results

Body and Liver weights

Figure 1 shows a comparison of the mean body and liver weight in different groups. The body and liver weight in various groups did not show significant differences with the sham and control groups ($P > 0.05$).

Findings of serum levels of glucose, ALT, AST, ALP, Alb, TP and TB

Figure 2 shows a comparison of mean serum glucose level in different groups. Glucose level in the TAM0.4 group showed a significant increase compared to the control and sham groups ($P < 0.05$). In the HECS

400 and HECS 800 groups, a significant decrease in glucose level was observed compared to the control and sham groups ($P < 0.05$). Also, in the HECS200, TAM0.4 + HECS400 and TAM0.4 + HECS800 groups, a significant decrease in glucose level was observed compared to the TAM0.4 group ($P < 0.05$).

Comparison of mean serum levels of ALT, ALP, AST, Alb, TP and TB in different groups. ALT and ALP levels is depicted in Fig. 3 A & B in the TAM0.4, TAM0.4 + HECS200, TAM0.4+HECS400

and TAM0.4 + HECS800 groups showed a significant increase compared to the control and sham groups ($P < 0.05$). In contrast, the HECS400 and HECS800 groups showed a significant decrease ($P < 0.05$). ALT and ALP levels in the HECS200, HECS400, HECS800, TAM0.4 + HECS200, TAM0.4 + HECS400 and TAM0.4 + HECS800 groups showed a significant decrease compared to the TAM0.4 group ($P < 0.05$). AST level (Fig. 3C) in the TAM0.4, TAM0.4 + HECS200, TAM0.4+HECS400 and TAM0.4 + HECS800 groups showed a significant increase compared to the control and sham groups ($P < 0.05$), in contrast, the HECS400 and HECS800 groups showed a significant decrease ($P < 0.05$). AST level in the HECS200, HECS400, HECS800, TAM0.4 + HECS400 and TAM0.4 + HECS800 groups showed a significant decrease compared to the TAM0.4 group ($P < 0.05$).

Albumin level (Fig. 3D) in the TAM0.4, TAM0.4 + HECS200 and TAM0.4 + HECS400 groups showed a

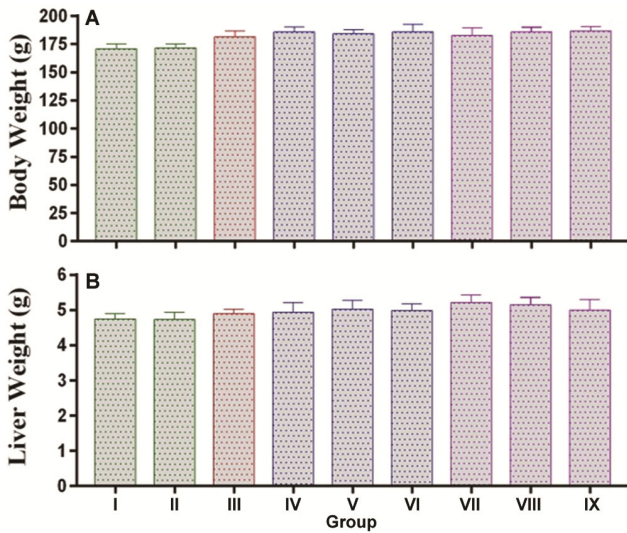


Fig. 1 — Comparison of mean body weight and liver weight in different groups. [Gr. I, control; Gr. II, sham; Gr. III, TAM0.4; Gr. (IV-VI), HECS200, HECS 400 and HECS 800 mg/kg, respectively; and Gr. VII, TAM0.4 + HECS200; Gr. VIII, TAM0.4 + HECS400; and Gr. IX, TAM0.4 + HECS800 mg/kg. * $P < 0.05$ compared to control; ** $P < 0.05$ compared to TAM0.4]

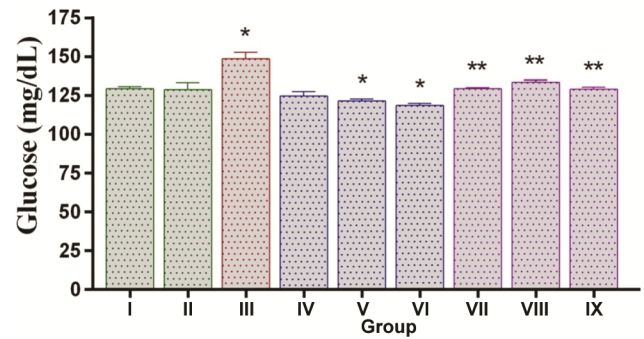


Fig. 2 — Comparison of mean serum glucose levels in different groups. [* $P < 0.05$ compared to control; ** $P < 0.05$ compared to TAM0.4]

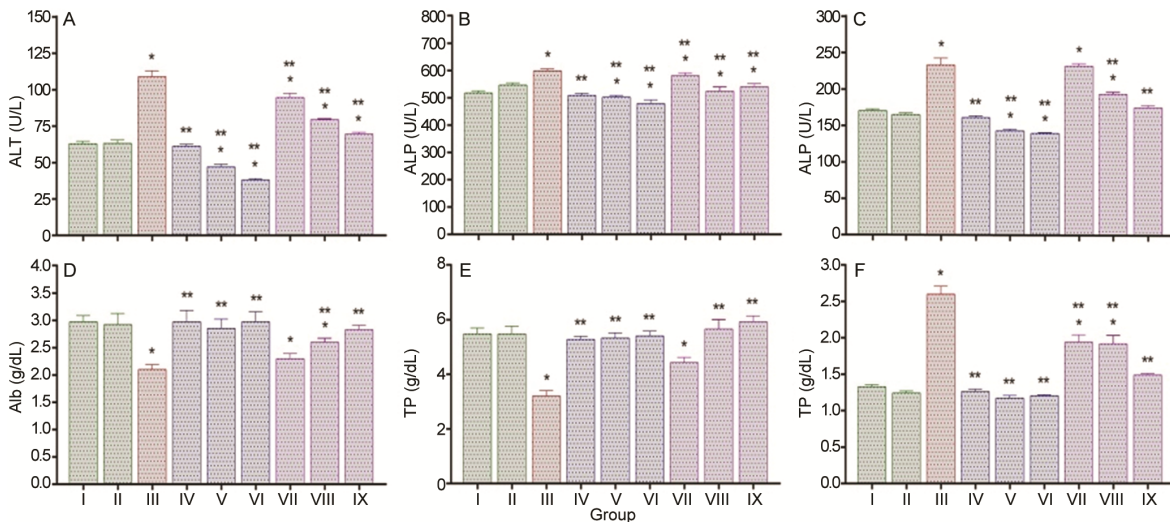


Fig. 3 — Comparison of mean serum levels of (A) alanine transaminase (ALT); (B)alkaline phosphatase (ALP); (C) aspartate transaminase (AST); and (D) albumin (Alb); (E) total protein (TP); and (F) total bilirubin (TB) in different groups. [* $P < 0.05$ compared to control; ** $P < 0.05$ compared to TAM0.4]

significant decrease compared to the control and sham groups ($P < 0.05$). Albumin level in the HECS200, HECS400, HECS800, TAM0.4 + HECS400 and TAM0.4 + HECS800 groups showed a significant increase compared to the TAM0.4 group ($P < 0.05$). TB level (Fig. 3E) in the TAM0.4 and HECS200 groups showed a significant decrease compared to the control and sham groups ($P < 0.05$). TB level in the HECS200, HECS400, HECS800, TAM0.4 + HECS400 and TAM0.4 + HECS800 groups showed a significant increase compared to the TAM0.4 group ($P < 0.05$). TB level (Fig. 3F) in the TAM0.4, TAM0.4 + HECS200 and TAM0.4 + HECS800 groups showed a significant increase compared to the control and sham groups ($P < 0.05$). TB levels in the HECS200, HECS400, HECS800, TAM0.4 + HECS200, TAM0.4 + HECS400 and TAM0.4 + HECS800 groups showed a significant decrease compared to the TAM0.4 group ($P < 0.05$).

Findings on Cat, SOD and GPX activity

Graph 4 shows the antioxidant status and levels of Cat, GPX and SOD enzymes in different groups. Cat and GPX levels (Fig. 4 A & B) in the TAM0.4 groups showed a significant decrease compared to the control and sham groups ($P < 0.05$), in contrast, Cat and GPX levels in the HECS200, HECS400, HECS800, TAM0.4 + HECS200, TAM0.4 + HECS400 and TAM0.4 + HECS800 showed a significant increase compared to the TAM0.4 ($P < 0.05$). SOD level (Fig. 4C) in the TAM0.4 and TAM0.4 + HECS200 groups showed a significant decrease compared to the control and sham groups ($P < 0.05$), in contrast, in the HECS200, HECS400, HECS800, TAM0.4 + HECS400 and TAM0.4 + HECS800 groups, they showed a significant increase compared to the TAM0.4 group ($P < 0.05$).

Histopathological findings

Histopathological findings of the liver are shown in Fig. 5. In the control, sham, HECS200, HECS400 and

HECS800 groups, hepatocytes were placed next to each other without damage and regularly, and no evidence of central venous damage was found. In the TAM0.4 group, significant structural changes were found in liver tissue compared to the control and sham groups. Necrosis, hyperemia, local inflammation, and vacuolar degradation were observed in liver tissue. Necrosis and local inflammation were reduced in the TAM0.4 + HECS200 and TAM0.4 + HECS400 groups compared to the TAM0.4 group and hepatocyte hyperemia was greatly reduced. In the TAM0.4 + HECS800 group, very mild histopathological changes and mild necrosis were observed.

Discussion

The present study indicated that the administration of TAM at a dose of 0.4 mg/kg had no effect on body weight and liver weight in adult male rats for 28 days. Consistent with this study, it has been reported that TAM has no effect on rats' body weight. This study shows that the administration of tamsulosin after 3, 6 and 8 weeks does not make a significant difference in rats' body weight¹⁹. Today, weight gain is a risk factor for diseases such as diabetes, cardiovascular diseases, liver disorders and cancer²⁰. It has been determined that alpha-1 adrenergic receptor blockers have a positive effect on total cholesterol and triglyceride levels²¹. The previous observations show that alpha-1 adrenergic blockers influence cholesterol and triglyceride synthesis by modulating low-density lipoprotein receptors that results in the suppression of HMG-CoA reductase (3-hydroxy-3-methyl-glutaryl-coenzyme A reductase), which is involved in the regulation of cholesterol in the liver²². It has also been suggested that alpha-1 adrenergic blockers may affect serum lipids by increasing the activity of lipoprotein lipase enzymes that determine the breakdown of very low-density lipoproteins²³. The results of this study showed that the TAM administration @0.4 mg/kg

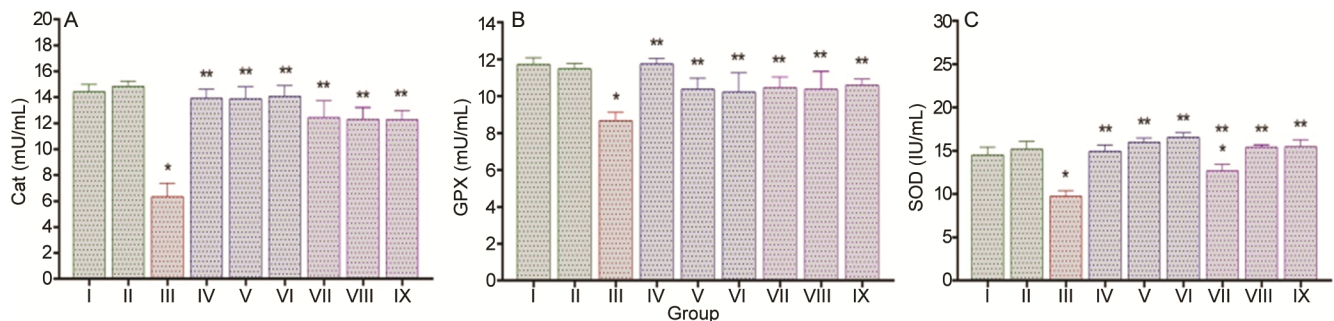


Fig. 4 — Comparison of mean serum levels of (A) catalase (CAT); (B) glutathione peroxidase (GPX); and (C) superoxide dismutase (SOD) in different groups. [* $P < 0.05$ compared to control; ** $P < 0.05$ compared to TAM0.4]

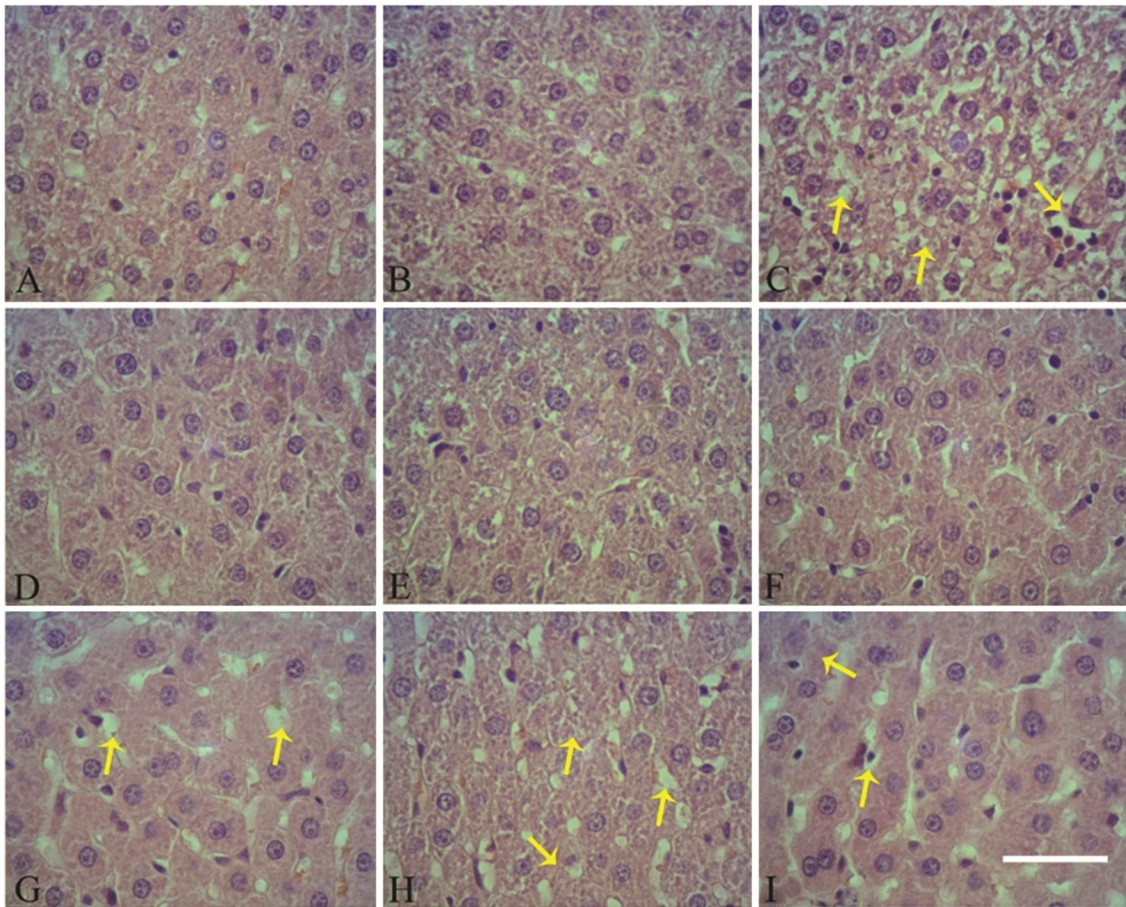


Fig. 5 — Photomicrograph of cross-section of rats' liver tissue in different groups. (A & B) In the control group, normal and regular structure with liver; (C) In the TAM0.4 group, necrosis (yellow arrow), hyperemia and tissue inflammation, Liver tissue damaged; (D, E & F) In HECS200, HECS400 and HECS800 groups, liver tissue normal and no tissue damage; (G & H) In TAM0.4+HECS200 and TAM0.4+HECS400 groups, moderate necrosis (yellow arrow), hyperemia and inflammation, Liver tissue damaged; and (I) In the TAM0.4+HECS800 group, very slight structural changes and very slight necrosis (yellow arrow) and Liver tissue damaged. [White scale bar: 30 μ m]

increases glucose levels and cause hyperglycemia in rats, a factor associated with glucose intolerance, beta cell dysfunction, and other metabolic syndrome problems that threaten general health¹⁹. Some studies show that alpha-1 adrenergic receptors play an important role in blood glucose homeostasis in laboratory animals and humans^{19,24,25}. Animal studies show that improved glucose uptake was observed when alpha-1 agonists were given to rats white fat cells to stimulate alpha-1 adrenergic receptors²⁶. Clinical studies also show that the stimulation of alpha-1 adrenergic receptors by alpha-1 agonists increases glucose uptake²⁷. In contrast, the inhibition of alpha-1 receptors leads to impaired tissue glucose uptake *in vitro* and *in vivo*²⁷⁻²⁹. Another possible mechanism that may be associated with impaired glucose uptake is the increase in plasma insulin levels. Inhibition of alpha-1 adrenergic receptors in

laboratory rats and human appears to have a negative effect on glucose tolerance, which ultimately increases plasma glucose concentrations^{26,30}.

The data from this study show that TAM has toxic effects on the liver and impairs liver function in rats. In this study, changes in ALT, AST, ALP, Alb, TP and TB levels indicate hepatotoxicity and increased cell permeability, which is also consistent with histopathological findings. Our study also shows that TAM-induced hepatotoxicity is consistent with Cat, SOD, and GPX activity, with decreased levels of all the three antioxidant enzymes. The production of free radicals and reactive oxygen species appear to play an important role in TAM-induced hepatotoxicity. The production of hydroxyl radicals (\cdot OH) may be associated with the pathogenesis of TAM-induced hepatotoxicity. The previous studies have shown that

the administration of TAM at a dose of 0.4 mg/kg in Balb/c rats is associated with increased nitric oxide (NO) production³¹. NO is a free radical that has an unpaired single electron and its overproduction causes tissue damage and pathological conditions. The reaction of O²⁻ with NO leads to the formation of ONOO⁻, which is much more reactive and toxic than its precursors, and can eventually form ·OH³². ·OH is a highly reactive radical and can react with unsaturated fatty acids in membrane phospholipids to produce free radicals which in turn react rapidly with oxygen to form peroxide. Then, these peroxides act as free radicals, leading to the elimination of most unsaturated fatty acids and extensive membrane damage³¹. As a mechanism, it is obvious that increasing NO reduces the activity of antioxidant enzymes, and thus liver damage³³. Contrary to the results of this study, *in vitro* studies indicate that TAM may possibly have anti-inflammatory effects. TAM appears to exert its inhibitory effects on proinflammatory agents by inhibiting the activity of NF-κB (nuclear factor kappa-light-chain-enhancer of activated B cells), which is involved in the activation of several inflammatory cytokines³⁴.

In recent years, herbal agents have been considered for their anti-inflammatory and anti-oxidative stress properties and, more importantly, are largely safe and non-toxic³⁵. In this study, the administration of HECS seeds had no effect on body weight and liver weight in adult male rats for 28 days, however, it reduced glucose levels in normal and TAM-treated rats, which is consistent with previous studies. HECS has been reported to have glucose-lowering effects in rats by inducing insulin secretion. HECS seems to be able to improve both the glucose and insulin levels and reduce insulin resistance^{11,13}. Also, the hypoglycemic effect of HECS may be due to increased insulin secretion from the remaining pancreatic β cells or protection of functional β cells against damage. It has been observed that treatment with the extract of CS seeds in alloxan-induced diabetic rats is associated with decreased blood glucose levels and increased insulin levels³⁶. Phenolic and flavonoid compounds in HECS can play an important role in improving blood glucose and antioxidant capacity in diabetic rats. These compounds can lower blood glucose levels by inhibiting the activity of alpha-amylase and alpha-glucosidase^{11,37}. Phenols and flavonoids have been shown to effectively suppress oxidative stress, enhance the antioxidant defense system, and regulate

the antioxidant/oxidant balance³⁸. Consistent with the results of this study, the administration of HECS in diabetic rats improved the level of antioxidant markers such as SOD and GPX, and in contrast, it reduced oxidative markers such as malondialdehyde (MDA)^{11,39}.

The results of this study showed that the administration of HECS, especially at a dose of 800 mg/kg in TAM-treated rats, improved serum levels of ALT, ALP, AST, Alb, TP and TB. There was also an increase in the activity of Cat, SOD and GPX antioxidant enzymes. Confirming these results, histopathological study of the liver showed that the reduction of necrosis and improvement of liver tissue increased from the minimum to the maximum dose, respectively, so that the lowest tissue damage was observed at the maximum dose. Oxidative stress and inflammation are important factors that play an important role in the pathogenesis of the liver, so the use of factors that can modulate oxidative stress and inflammation can prevent and manage liver diseases. *Coronillasecuridaca* seeds are one of these factors that have the ability to prevent oxidative stress and inflammation⁴⁰. Animal studies show that flavonoids are effective in reducing oxidative stress and lipid peroxidation⁴¹. Flavonoids are among the plant antioxidants that have anti-fibrotic and anti-cancer properties and therefore can prevent liver fibrosis. Flavonoids exert their anti-fibrotic effects by inhibiting the activity of NF-κB and TNF-α (Tumor necrotizing factor Alpha). In addition, flavonoids prevent the accumulation of extracellular matrix protein by promoting apoptosis in active liver star cells and prevent the progression of hepatic fibrosis⁴². It has been determined that the extract of SS seeds can increase the expression of antioxidant enzymes such as SOD, while reducing oxidative factors such as MDA⁴¹. It has been shown that the administration of HECS seeds at doses of 50, 100 and 200 mg/kg for 5 weeks in hypercholesterolemic rats fed high fat diet reduces serum lipid levels, inhibits lipid peroxidation and improves liver tissue damage⁴³.

It has been reported that the administration of CS seeds' extract at doses of 100, 200 and 400 mg/kg for 5 weeks in streptozotocin-induced diabetic rats reduces proinflammatory cytokines such as IL-1, IL-6 and TNF-α, while increasing the anti-inflammatory cytokine IL-10. However, in this study, no change in serum levels of ALT, AST, GGT and ALP of streptozotocin-induced diabetic rats was observed, however, the administration of doses of 200 and 400 mg/kg of

HECS seeds improved liver damage³⁹. The studies show that NO level increases in rats with closed bile ducts. However, the administration of HECS at doses of 100 and 200 mg/kg decreased NO levels in liver tissue. HECS appears to reduce the expression of the iNOS gene, which encodes the NO synthase enzyme⁴⁰. NO is a highly reactive molecule that can be produced in hepatocytes following oxidative stress. HECS seems to be able to counteract nitrogen-active species such as NO at the cellular level, thereby reducing oxidative stress and preventing or protecting liver damage^{40,44}. In the present study, it can be assumed that HECS has protected against liver damage by affecting the oxidative stress caused by TAM and has improved blood parameters and the level of antioxidant activity of the liver. In this study, the use of 800 mg/kg HECS was more effective than the doses of 200 and 400 mg/kg that this finding indicates that HECS at higher doses has no toxic effects on liver tissue. TGF β -1 is a profibrogenic cytokine that the inhibition of its activity reduces liver damage. HECS administration has been shown to reduce TGF β -1 expression in rats with closed bile ducts^{40,45}. Comparatively, the effectiveness of HECS and vitamin C has been studied and HECS has been shown to be more effective than vitamin C supplement. *Coronillasecuridaca* L. extract has been shown to contain ascorbic acid, phenolic compounds and flavonoids, and these compounds appear to have synergistic effects in the extract^{11,40}.

Overall, our findings showed that compared to HECS doses of 200 and 400 mg/kg, 800 mg/kg dose was more effective in reducing TAM-induced liver damage in male rats. Histopathological evaluation of the liver confirmed the effectiveness of 800 mg/kg HECS in reducing necrosis and improving liver tissue. Contrary to the results of this study, it has been reported that HECS is more effective at lower doses, which may be due to reduced absorption of HECS at higher doses⁴⁰. However, consistent with this study, it has been shown that different doses of HECS significantly reduce oxidative stress and inflammation in diabetic rats, and the effects of higher doses is greater¹¹. The most important limitations of this study are the short study period, non-use of higher doses of HECS, lack of measurement of oxidative factors such as MDA and lack of evaluation of apoptosis at the tissue level. Therefore, it is suggested that these cases be considered in future studies.

Conclusion

The administration of tamsulosin(TAM)@ 0.4 mg/kg of body wt. for 28 days in adult male rats had no effect on body weight or liver weight. However, it disrupted serum levels of glucose, alanine transaminase (ALT), aspartate transaminase (AST), alkaline phosphatase (ALP), albumin (Alb), total protein (TP) and total bilirubin (TB). Also, the activity of antioxidant enzymes [catalase (Cat), superoxide dismutase (SOD)and glutathione peroxidase (GPX)] decreased. The administration of TAM alone caused necrosis and the destruction of liver tissue. However, the administration of HECS at a dose of 800 mg/kg of body wt. had the greatest effect on improving the biochemical parameters of blood and liver tissue. The effect of HECS seems to be dose-dependent and has the greatest effect at higher doses. Therefore, it is suggested that CS be considered as a supplement to counteract the cytotoxic effects of TAM on liver tissue.

Ethical statement

In all stages of the study, the ethical and practical principles of working with laboratory animals were followed in accordance with the instructions of the Ethics Committee of the Islamic Azad University, Kazerun Branch, Fars, Iran (ethics code number: IR.IAU.KAU.REC.1400.195).

Conflict of interest

Authors declare no competing interests.

References

- 1 Gwon YN, Park JJ, Yang WJ, Doo SW, Kim JH & Kim DK, Comparing effects of alpha-blocker management on acute urinary retention secondary to benign prostatic hyperplasia: A systematic review and network meta-analysis. *Prostate Int*, 11(2) (2023) 9.
- 2 Jiménez Sánchez J, Serrano Díaz L & Martínez Crespo JJ, Acute hepatocellular drug-induced liver injury probably caused by doxazosin. *Rev Esp Enferm Dig*, 113 (4) (2021) 301.
- 3 Franco JVA, Tesolin P & Jung JH, Update on the management of benign prostatic hyperplasia and the role of minimally invasive procedures. *Prostate Int*, 11 (2023) 1.
- 4 Aronson JK. *Meyler's Side Effects of Drugs. The International Encyclopedia of Adverse Drug Reactions and Interactions*, 16th edn, (Elsevier, Amsterdam, Netherlands), 2016, pp. 702.
- 5 Zhou Z, Cui Y, Wu J, Ding R, Cai T & Gao Z, Meta-analysis of the efficacy and safety of combination of tamsulosin plus dutasteride compared with tamsulosin monotherapy in treating benign prostatic hyperplasia. *BMC Urol*, 19 (2019) 17.
- 6 Low EXS, Zheng Q, Chan E & Lim SG. Drug induced liver injury: East versus West - a systematic review and meta-analysis. *ClinMolHepatol*, 26 (2020) 142.

- 7 Fremond L, Diebold MD & Thieffn G, He'patiteaigue" pseudo-angiocholitiqeprobablementinduitepar la tamsulosine. [Acute pseudoangiocholitic hepatitis probably induced by tamsulosin]. *Gastroenterol Clin Biol*, 30 (2006) 1224.
- 8 Olayinka ET & Adewole KE, Ameliorative effect of morin on dutasteride-tamsulosin-induced testicular oxidative stress in rat. *J Complement Integr Med*, 18 (2020) 327.
- 9 Duan B & Wang X, The effectiveness of tamsulosin hydrochloride with terazosin combination therapy for chronic prostatitis Type-III b. *Pak J Med Sci*, 38 (2022) 595.
- 10 Eleazu C, Eleazu K & Kalu W, Management of Benign Prostatic Hyperplasia: Could Dietary Polyphenols Be an Alternative to Existing Therapies? *Front Pharmacol*, 8 (2017) 234.
- 11 Alizadeh-Fanalou S, Babaei M, Hosseini A, Azadi N, Nazarizadeh A, Shojaii A, Borji M, Malekinejad H & Bahreini E, Effects of *Securigera securidaca* seed extract in combination with glibenclamide on antioxidant capacity, fibroblast growth factor 21 and insulin resistance in hyperglycemic rats. *J Ethnopharmacol*, 248 (2020) 112331.
- 12 Cai T, Cui Y, Yu S, Li Q, Zhou Z & Gao Z, Comparison of Serenoarepens with tamsulosin in the treatment of benign prostatic hyperplasia: a systematic review and meta-analysis. *Am J Mens Health*, 14 (2020) 1557988320905407.
- 13 Rajaei Z, Moradi R, Ghorbani A & Saghebi A, Antihyperglycemic and antihyperlipidemic effects of hydroalcoholic extract of *Securigera securidaca* seeds in streptozotocin-induced diabetic rats. *Adv Biomed Res*, 4 (2015) 33.
- 14 Babaei M, Alizadeh-Fanalou S, Nourian A, Yarahmadi S, Farahmandian N, Nabi-Afjadi M, Alipourfard I & Bahreini E, Evaluation of testicular glycogen storage, FGF21 and LDH expression and physiological parameters of sperm in hyperglycemic rats treated with hydroalcoholic extract of *Securigera securidaca* seeds, and Glibenclamide. *Reprod Biol Endocrinol*, 19 (2021) 104.
- 15 Kohestani Y, Kohestani B, Shirmohamadi Z & Faghani M, Effect of tamsulosin on testis histopathology and serum hormones in adult rats: Experimental study. *Int J Reprod Biomed*, 18 (2020) 531.
- 16 *PubChem Compound Summary for CID 129211*, Tamsulosin. [PubChem (Internet). National Library of Medicine (US), National Center for Biotechnology Information; Bethesda, MD, USA), 2004. <https://pubchem.ncbi.nlm.nih.gov/compound/129211>.
- 17 El-Borady OM, Othman MS, Atallah HH & Abdel Moneim AE, Hypoglycemic potential of selenium nanoparticles capped with polyvinyl-pyrrolidone in streptozotocin-induced experimental diabetes in rats. *Heliyon*, 6 (2020) e04045.
- 18 Farashbandi AL, Shariati M & Mokhtari M, Comparing the Protective Effects of Curcumin and Ursodeoxycholic Acid after Ethanol-Induced Hepatotoxicity in Rat Liver. *Ethiop J Health Sci*, 31 (2021) 673.
- 19 Dikko M, Sarkingobir Y & Umar AI, Effect of Tamsulosin Administration on oral glucose tolerance (ogt) in normal Wistar rats. *Niger J PhysiolSci*, 35 (2020) 187.
- 20 Yazici-Tutunis S, Gurel-Gurevin E, Ustunova S, Demirci-Tansel C & Mericli F, Possible effects of *Phillyrea latifolia* on weight loss in rats fed a high-energy diet. *Pharma. Biol*, 54 (2016)1991.
- 21 Kabra NK, Alpha blockers and metabolic syndrome. *J Assoc Physicians India*, 62 (2014) 13.
- 22 Katzung BG, Drug receptors and pharmacodynamics. *Basic Clin Pharmacol*, 9th ed. (McGraw-Hill Medical, NY, USA), 2004, pp. 17.
- 23 Enroth S, Maturi V, Berggrund M, Enroth SB, Moustakas A & Johansson A, Systemic and specific effects of antihypertensive and lipidlowering medication on plasma protein biomarkers for cardiovascular diseases. *Sci Rep*, 8 (2018) 5531.
- 24 Wei L, Lai EC, Kao-Yang YH, Walker BR, MacDonald TM, & Andrew R, Incidence of type 2 diabetes mellitus in men receiving steroid 5 α -reductase inhibitors: population based cohort study. *Br Med J*, 365 (2019) 11204.
- 25 Shi T, Papay RS & Perez DM, The role of α 1-adrenergic receptors in regulating metabolism: increased glucose tolerance, leptin secretion and lipid oxidation. *J Recept Signal Transduct Res*, 37 (2017) 124.
- 26 Perez DM, Current Developments on the Role of α 1-Adrenergic Receptors in Cognition, Cardioprotection, and Metabolism. *Front Cell Dev Biol*, 9 (2021) 652152.
- 27 Papay RS & Perez DM, α 1-Adrenergic receptors increase glucose oxidation under normal and ischemic conditions in adult mouse cardiomyocytes. *J Recept Signal Transduct Res*, 4 (2021) 138.
- 28 Shivaprasad GM, Bharatha A, Naikwadi AA & Wali RS, Effect of tamsulosin a selective α 1-antagonist on glucose homeostasis in rats. *Int J Pharm PharmSci*, 7 (2015) 232.
- 29 Moustaki M, Paschou SA, Vakali E, Xekouki P, Ntali G, Kassi E, Peppas M, Psaltopoulou T, Tzanela M & Vryonidou A, Secondary diabetes mellitus in pheochromocytomas and paragangliomas. *Endocrine*, 82 (2023) 467.
- 30 Al-Mourad FH & Saadé NE, Neural regulation of intestinal nutrient absorption. *Prog Neurobiol*, 95 (2011):149.
- 31 Phaniendra A, Jestadi DB & Periyasamy L, Free radicals: properties, sources, targets, and their implication in various diseases. *Indian J ClinBiochem*, 30 (2015) 11.
- 32 So MJ & Cho EJ, Phloroglucinol attenuates free radical-induced oxidative stress. *Prev Nutr Food Sci*, 19 (2014) 129.
- 33 Chaudhary P, Janmeda P, Docea AO, Yeskaliyeva B, AbdullRazis AF, Modu B, Calina D & Sharifi-Rad J, Oxidative stress, free radicals and antioxidants: potential crosstalk in the pathophysiology of human diseases. *Front Chem*, 11 (2023) 1158198.
- 34 Sun L, Sun C, Zhou S, Zhang L & Hu W, Tamsulosin attenuates high glucose-induced injury in glomerular endothelial cells. *Bioengineered*, 12 (2021) 5184.
- 35 Qiao J, Gan Y, Gong Y, Song Q, Zhang B, Li B, Ru F, Li Y & He Y, Combination therapy with curcumin plus tamsulosin and finasteride in the treatment of men with benign prostatic hyperplasia: a single center, randomized control study. *Transl Androl Urol*, 10 (2021) 3432.
- 36 Pouramir M, Shahaboddin ME, Moghadamnia AA & Parastouei K, To study the effects of *Securigera securidaca* (L.) seed against alloxan-induced hyperglycemia. *J Med Plants Res*, 5 (2011) 3188.
- 37 Rasouli H, Hosseini-Ghazvini SM, Adibi H & Khodarahmi R, Differential alpha amylase/alpha-glucosidase inhibitory activities of plant-derived phenolic compounds: a virtual screening perspective for the treatment of obesity and diabetes. *Food Funct*, 8 (2017) 1942.

- 38 Bahadoran Z, Mirmiran P & Azizi F, Dietary polyphenols as potential nutraceuticals in management of diabetes: a review. *J Diabetes MetabDisord*, 12 (2013) 43.
- 39 Kiani B, Alizadeh-Fanalou S, Khomari F, Babaei M, Alipourfard I, Kalantari Hesari A, Najafi M, Sharifi AM & Bahreini E, The effect of hydroalcoholic seed extract of *Securigera securidaca* on the hepatic renin-angiotensin system in the streptozotocin-induced diabetic animal model. *ClinDiabetol*, 11 (2022) 97.
- 40 Nasehi Z, Kheiripour N, Taheri MA, Ardjmand A, Jozi F, Aghadavod E, Doustimotlagh AH & Shahaboddin ME, The protective effects of *Securigera securidaca* seed extract on liver injury induced by bile duct ligation in rats. *Biomed Res Int*, 2022 (2022) 6989963.
- 41 Alizadeh-Fanalou S, Nazarizadeh A, Babaei M, Khosravi M, Farahmandian N & Bahreini E, Effects of *Securigera securidaca* (L.) Degen & Dorfl seed extract combined with glibenclamide on paraoxonase1 activity, lipid profile and peroxidation, and cardiovascular risk indices in diabetic rats. *Bioimpacts*, 10 (2020) 159.
- 42 Li S, Tan HY, Wang N, Cheung F, Hong M & Feng Y, The potential and action mechanism of polyphenols in the treatment of liver diseases. *Oxid Med Cell Longev*, 2018 (2018) 8394818.
- 43 Garjani A, Fathiazad F, Zakheri A, Akbari NA, Azarmie Y, Fakhrjoo A, Andalib S & Maleki-Dizaji N, The effect of total extract of *Securigera securidaca* L. seeds on serum lipid profiles, antioxidant status, and vascular function in hyper-cholesterolemic rats. *J Ethnopharmacol*, 126 (2009) 525.
- 44 Bryan N & Grisham M, Methods to detect nitric oxide and its metabolites in biological samples. *Free Radic Biol Med*, 43 (2007) 645.
- 45 Hafez MM, Hamed SS, El-Khadragy MF, Hassan ZK, Al Rejaie SS, Sayed-Ahmed MM, Al-Harbi NO, Al-Hosaini KA, Al-Harbi MM, Alhoshani AR, Al-Shabanah OA & Alsharari SD, Effect of ginseng extract on the TGF- β 1 signaling pathway in CCl₄-induced liver fibrosis in rats. *BMC Complement Altern Med*, 17 (2017) 45.