



Gastroprotective effect of *n*-butanol fractions from *Lumnitzera racemosa* leaves against indomethacin induced ulcer in Wistar rats

Ahmed Gomaa Gomaa Darwish^{1,2,†}, Mamdouh Nabil Samy^{3,†,*}, Magda Ewies Mahmoud¹ & Katsuyoshi Matsunami⁴

¹Department of Biochemistry, Faculty of Agriculture, Minia University, Minia 61519, Egypt

²College of Agriculture & Food Sciences, Florida A&M University, Tallahassee, FL 32307, USA

³Department of Pharmacognosy, Faculty of Pharmacy, Minia University; Minia 61519, Egypt

⁴Department of Pharmacognosy, Graduate School of Biomedical and Health Sciences, Hiroshima University; 1-2-3 Kasumi, Minami-ku, Hiroshima 734-8553, Japan

Received 12 May 2020; revised 30 December 2020

Phytoconstituents from plants serve as a safe replacement for synthetic molecules in drug production. *Lumnitzera racemosa* Willd., commonly called white-flowered black mangrove, is used in folk medicine to treat inflammation and other diseases. Here, we evaluated the antiulcer activity of two fractions (LR-B-4-11 and LR-B-4-12) of *n*-butanol (*n*-BuOH) fractions of *L. racemosa* leaves at the doses of 50 and 100 mg/kg, body wt. against indomethacin induced gastric mucosal injury in Wistar rats. The rats were dissected and their stomachs were inspected macroscopically to diagnose hemorrhagic lesions in the gastric and fundic mucosa. Administration of the fractions at doses of 50 and 100 mg/kg body wt., demonstrated a significant reduction in the indomethacin induced gastric erosion when compared to the control. The lower dose of LR-B-4-11 fraction (50 mg/kg) resulted in better inhibition of indomethacin induced gastric ulcer as compared to the control. Histological studies of the fundic and gastric mucosa reported that indomethacin led to mucosal degeneration, ulceration, and migration of numerous inflammatory cells throughout the section. On the other hand, pretreated groups with *n*-BuOH fractions demonstrated substantial regeneration of the mucosal layer and significant prevention of hemorrhage and edema occurrence.

Keywords: Antiulcer activity, Folk medicine, Gastric ulcers, Inflammation, Mangrove, Mucosal degeneration, White-flowered black mangrove

Gastric ulcer is a common serious disease that affects the whole gastrointestinal tract¹. It strikes primarily in the stomach and the proximal duodenum and may occur in the anastomotic site of the esophagus, jejunum and stomach². A peptic ulcer results from a disparity between some endogenous forceful factor(s) [hydrochloric acid, pepsin, refluxed bile, leukotrienes, and reactive oxygen species (ROS)] and cytoprotective factors, including the role of the mucus-bicarbonate barrier, surface-active phospholipids, prostaglandins (PGs), mucosal blood flow, cell regeneration, and migration, non-enzymatic and enzymatic antioxidants and certain growth factors³⁻⁶. Gastric ulcer mechanism as described in many scientific articles is still poorly understood. It is a complicated disease in which

different risk factors may lead to increased gastric damage such as lifestyle stress, alcohol consumption, use of nonsteroidal anti-inflammatory drugs (NSAIDs), and drugs that stimulate the secretion of gastric acid and pepsin, smoking, and family history^{3,7}. One of the most vital challenges in medicine today is the anticipation of peptic ulcers, as it is certainly a major human disease affecting nearly 8 to 10 % of the world's population⁸, and of these 5% suffers from gastric ulcers³. This disease occurs more often in males than in females⁹.

Lumnitzera racemosa Willd. (Combretaceae), commonly called white-flowered black mangrove, is a small tree located on the coast of Africa, India, Australia, and Asia. A fluid collected from incisions made in the stem is used for the treatment of itches. Recently, the antihypertensive activity of the plant's aqueous acetone extract has been stated. Marine halophytes, such as mangroves and associated plants,

*Corresponding author:

E-Mail:mamdouhnabil.2006@yahoo.com;

mamdouh,eskandr@mu.edu.eg

†Equal contribution

possess a range of different metabolites having antioxidant, anti-inflammatory, antimicrobial, antidiarrheal, hepatoprotective, antifeedant, insecticidal, cytotoxic, and antiplasmodial actions. A large number of compounds such as long-chain rubber like polyisoprenoid alcohols in leaves, flavonoids, tannins, lignans, and long-chain fatty acids have been recorded for this plant, in addition to low molecular weight carbohydrates¹⁰⁻¹⁹.

Previous phytochemical study of LR-B-4-11 and LR-B-4-12 fractions of *n*-BuOH extract of *L. racemosa* leaves led to the isolation and identification of 9 compounds. The structures of compounds were determined to be myricetin 3-*O*-methyl glucuronate (1), lumniracemoside (2), *n*-hexanol 1-*O*-rutinoside (3), 1,3,6-tri-*O*-galloyl- β -D-glucopyranose (4), corilagin (5), myricetrin (6), mixture of myricetin 3-*O*- β -D-glucopyranoside and myricetin 3-*O*- β -D-galactopyranoside (7 and 7') 1,2,3,4,6-penta-*O*-galloyl- β -D-glucopyranose (8), and quercetin 3-*O*-rutinoside (9)¹⁷.

In study we evaluated the antiulcer activity of the chemical constituents of LR-B-4-11 and LR-B-4-12 fractions of *n*-BuOH extract of *Lumnitzera racemosa* collect from the subtropical marine regions in Okinawa, Japan against indomethacin-induced gastric mucosal injury in Wistar rats.

Materials and Methods

Plant material

The leaves of *Lumnitzera racemosa* were obtained from Okinawa, Japan. The plant was kindly identified by Prof. T. Shinzato. A voucher specimen of the plant was kept at the Herbarium of Hiroshima University (LR-Okinawa-0825).

Extraction

The air dried powdered leaves of *L. racemosa* (4.1 kg) were extracted with 95% methanol until exhaustion and then concentrated to produce a viscous gummy residue under reduced pressure using Eyela rotary evaporator (Tokyo Rikakikai, Japan). The residue was dissolved in water and defatted with *n*-hexane to give a hexane layer (58.8 g). The aqueous layer was evaporated to remove a small quantity of *n*-hexane and then extracted with ethyl acetate (EtOAc) (139.1 g) and *n*-BuOH (89.9 g), respectively.

The *n*-BuOH fraction (89.9 g) was fractionated by column chromatography on Diaion HP-20 (Φ =80 mm, L=37cm). The column was developed firstly with H₂O, followed by MeOH-H₂O stepwise gradient with increasing MeOH and finally with 100% MeOH. The

identical fractions have been combined to afford eight fractions (LR-B-1 to LR-B-8).

The fraction LR-B-4 (31.8 mg) was chromatographed over silica gel (900 g), (Φ = 80 mm, L = 44 cm), using CHCl₃, then CHCl₃-MeOH gradient system. The related fractions have been combined producing 14 fractions (LR-B-4-1 to LR-B-4-14).

Antiulcer activity experiment

Thirty-six male Wistar rats were purchased from Animal house, Faculty of Agriculture, Department of Agricultural Chemistry, Minia University, Egypt. The animals received 2 weeks of acclimation duration, during which they were fed a regular rat pellet diet and water *ad libitum*, with an alternating 12 h dark/light cycle, and a steady ambient temperature of 21 and 25°C. They were kept separately in cages for different six groups (6 rats each), and each group had a mean weight of 147±2 g. The food was removed the day before the injection, with free access to water. All experiments were conducted on experimental animals were approved by the Commission on the Ethics of Scientific Research, Faculty of Pharmacy, Minia University, Egypt (Project code No. 46/2019). Six rats per group were distributed randomly up to the mean weight distribution, as follows: Protective treated Groups I & II: administered with indomethacin and LR-B-4-11 fraction (1% DMSO) at 50 and 100 mg/kg body wt. orally once daily in the morning, respectively; similarly, Groups. III & IV: administered with indomethacin and LR-B-4-12 fraction (1% DMSO) at 50 and 100 mg/kg body wt. orally once daily in the morning; and Group V indomethacin group in which gastric ulceration was induced by intraperitoneal (i.p.) injection of a single dose of 30 mg/ kg/body wt.²⁰; and Group VI, DMSO group administered with 1% DMSO orally once daily in the morning.

Indomethacin oral administration (30 mg/kg/ body wt.) for Groups I-IV were followed the morning oral protection treatments either with (LR-B-4-11 and LR-B-4-12) fractions by 30 min. Food intake and body weight were determined and the biological experiment has lasted for 10 days. The animals were sacrificed and the stomach was excised and cut along the greater curvature for all animals and washed carefully with 5 mL of 0.9% NaCl. Histological examination was studied to determine the severity of the ulcers²¹.

Gastric secretion study

The collected gastric juice from the stomach of rats was centrifuged and the supernatant was expressed in terms of mL/100 g body wt. One milliliter of

gastric juice was pipetted into a 100 mL conical flask, two or three drops of Topfer's reagent were added and this was titrated with 0.01 N NaOH until the colour of the solution changed from red to yellowish orange. The volume of added alkali was observed. This volume is equivalent to free acidity. Two or three drops of a solution of phenolphthalein were added and continued the titration till a definite red colour tinge developed. The total volume of alkali added was noted. The volume represents the total acidity^{22,23}. Acidity was calculated using the following formula:

$$\text{Acidity (meq/L/100 g)} = (\text{Volume of NaOH} \times \text{Normality of NaOH} \times 100) / 0.1$$

Histological examination

Animals were sacrificed at the end of the experiments, while they were under isoflurane (5% in 100% oxygen) anesthesia. For the histological investigation, specimens of each rat's gastric walls were stored in 10% buffered formalin for 24 h, following the antiulcer activity evaluation. The tissue specimens were then handled for paraffin embedding tissue sections. The samples were cut using a Minux-rotary microtome, followed by staining with Hematoxylin and Eosin (H & E) and mounted on Canada balsam. All sections were examined under a light microscope. Photographs of the lesions were taken using an Olympus photo microscope to detect and record histopathological changes, such as edema, inflammation, infiltration, and erosion, etc.²⁴.

Induction of ulcer

The animals were denied access to any nutrition for a day and were only allowed access to drinking water for two hours prior to the beginning of the experiment. The rats were placed individually in

separate cages during the fasting period to prevent coprophagy. Thirty minutes after pre-treatment with test samples (50 and 100 mg/kg body wt.), gastric ulcers induced using a single dose of 30 mg/kg body wt. indomethacin²⁰.

Solvents and chemicals

Indomethacin was purchased from Nile Co., for Pharmaceutical Industries (Cairo, Egypt). The other chemicals used were of good quality and analytical grade.

Statistical analysis

The collected data were statistically analyzed using the ANOVA procedure (Excel, 2016). The significance levels were accepted with $P < 0.05$.

Results

Effect of *n*-BuOH extract of *L. racemosa* leaves on gastric secretion

The effects of LR-B-4-11 and LR-B-4-12 fractions of *n*-BuOH extract of *L. racemosa* leaves at doses of 50 and 100 mg/kg on pH, free and total acidity was studied by collecting gastric juice from stomachs. As shown in Table 1, treatment with LR-B-4-11 and LR-B-4-12 fractions at a dose of 50 mg/kg body weight has significantly reduced the free acidity by 44.91 and 32.05%, respectively, and accompanied by significant reductions in volumes of gastric juice and gastric pH (Table 1). On the other side, a dose of 100 mg/kg body wt. has decreased the total acidity by 30.41 and 31.44 %, respectively compared to control (Table 1).

Macroscopic examination of gastric lesions

Indomethacin caused lesions manifested by thick blackish areas scattered over the major part of the mucosa, compared to the normal control (Fig. 1).

Table 1 — Estimation of pH, free acidity and total acidity of gastric juice

Treatment	Volume of gastric juice (mL)	pH	Free acidity (meq/L/100 g)	Total acidity (meq/L/100 g)
LR-B-4-11 (50 mg/kg)	4.06±0.08	1.51±0.08	15.21±1.94	60.60±2.176
LR-B-4-11 (100 mg/kg)	3.46±0.05	2.10±0.05	21.49±0.42	54.60±1.430*
LR-B-4-12 (50 mg/kg)	4.70±0.15	1.80±0.15	18.76±0.55	57.00±1.167*
LR-B-4-12 (100 mg/kg)	3.73±0.02	2.23±0.02	22.31±2.34	53.20±0.32
IND (30 mg/kg) DMSO 1%	1.25±0.23 1.89±0.43	1.30±0.21 2.76±0.34	24.13±1.65 27.61±2.71	66.30±2.14 77.60±3.23

[Each value is the mean ± SD of triplicate measurements].

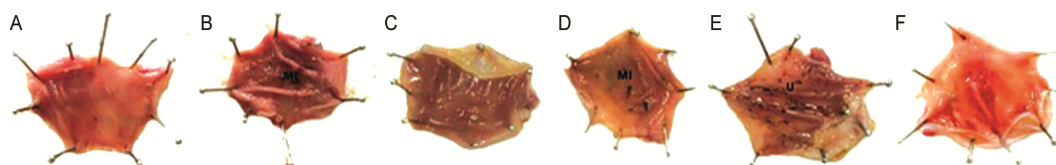


Fig. 1 — Gross appearance of the gastric mucosa in pretreated group with: (A) LR-B-4-11, 50 mg/kg body wt.; (B) LR-B-4-11, 100 mg/kg body wt.; (C) LR-B-4-12, 50 mg/kg b.w.; (D) LR-B-4-12, 100 mg/kg body wt.; (E) indomethacin; and (F) DMSO (control group). [U: marked ulcers along with haemorrhagic streaks and mucosal damage were observed and MI: mild injuries]

Mild ulcerations were observed after pre-treatment with LR-B-4-11 and LR-B-4-12 fractions of *n*-BuOH extract of *L. racemosa* leaves, especially at the dose of 100 mg/kg (Fig. 1 B & D). At the dose of 50 mg/kg, the fractions exhibited remarkable inhibition of indomethacin-induced ulcers. (Fig. 1 A & C)

Histological evaluation of gastric lesions

The effects of LR-B-4-11 and LR-B-4-12 fractions of *n*-BuOH extract of *L. racemosa* leaves at doses of 50 and 100 mg/kg on various histopathological parameters in indomethacin-induced gastric ulcer compared to other groups are shown in Table. 2. The fraction LR-B-4-11 at the lower dose (50 mg/kg) exhibited better inhibition of indomethacin-induced gastric ulcer as compared to the control.

A photomicrograph of a section in fundic mucosa is shown in Fig. 2. Group VI showed fundic gland

Table 2 — Effects of *n*-BuOH fractions of *L. racemosa* leaves on various histopathological parameters in indomethacin induced gastric ulcer

Group	Mucosal damage	Congested BV	Collagen deposition	Inflammatory cells
LR-B-4-11 (50 mg/kg)	-	-	-	-
LR-B-4-11 (100 mg/kg)	+++	+++	+++	+++
LR-B-4-12 (50 mg/kg)	-	+	+	+
LR-B-4-12 (100 mg/kg)	++	+++	+++	+++
IND (30 mg/kg)	-	++	++	++
DMSO 1%	-	-	+	-

Present (+); Non present (-); BV, Blood vessels

with apical surface epithelium with clear boundaries and muscularis mucosa (Fig. 2F).

The histological section of the gastric mucosa is shown in Fig. 3. Group VI displayed some collagen deposition in submucosa (Fig. 3F). Whereas the indomethacin group V demonstrated ulceration throughout the gastric mucosal section (Fig. 3E) and showed intact gastric surface mucus layer, inflammatory cell infiltration, local congestion, and edema in lamina propria in the section of fundic mucosa (Fig. 2E). However, administration of *n*-BuOH fractions (LR-B-4-11 and LR-B-4-12) at the lower concentration (50 mg/kg body wt.) showed a significant change in histopathology of the fundic mucosa (Fig. 2 A & C), compared to the higher concentration (100 mg/kg) (Fig. 2 B & D). The histopathology of the gastric mucosa for the *n*-BuOH fractions (LR-B-4-11 and LR-B-4-12) at the lower concentration (50 mg/kg) presented some collagen deposition in sub mucosa (Fig. 3A) and few collagen fibers in the lamina propria between the basal parts of the fundic glands and in sub mucosal areas (Fig. 3C). On the other hand, the photomicrograph of the gastric mucosa at the higher concentration of (LR-B-4-11 and LR-B-4-12) displayed ulcer (U) with very thick collagen fibers in submucosal areas (Fig. 2 B & D and Fig. 3 B & D).

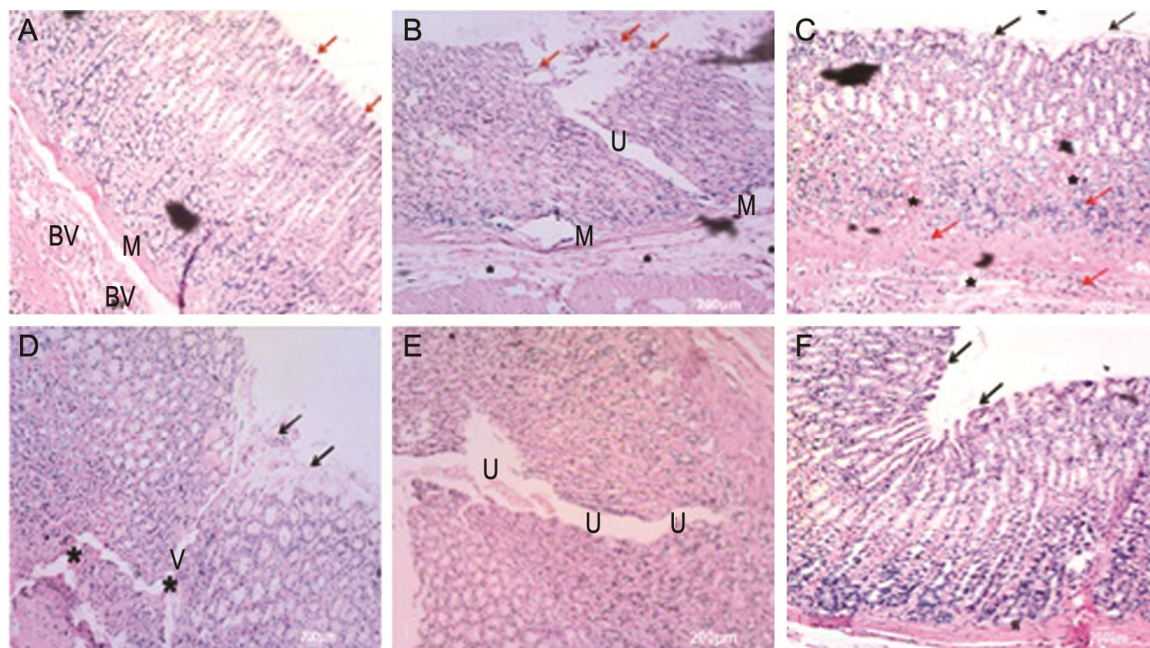


Fig. 2 — A photometric of a section in fundic mucosa in pretreated group with: (A) LR-B-4-11, 50 mg/kg body wt.; (B) LR-B-4-11, 100 mg/kg body wt.; (C) LR-B-4-12, 50 mg/kg body wt.; (D) LR-B-4-12, 100 mg/kg body wt.; (E) indomethacin; and (F) DMSO (control group). [Each group was assessed at 400X magnification (H&E, scale bar=200 µm); →:clear boundaries, M: muscularis mucosa, BV: congested blood vessels in submucosa, L: loss of some cells in the basal part of the fundic gland, *: submucosal odema and U: gastric ulcer]

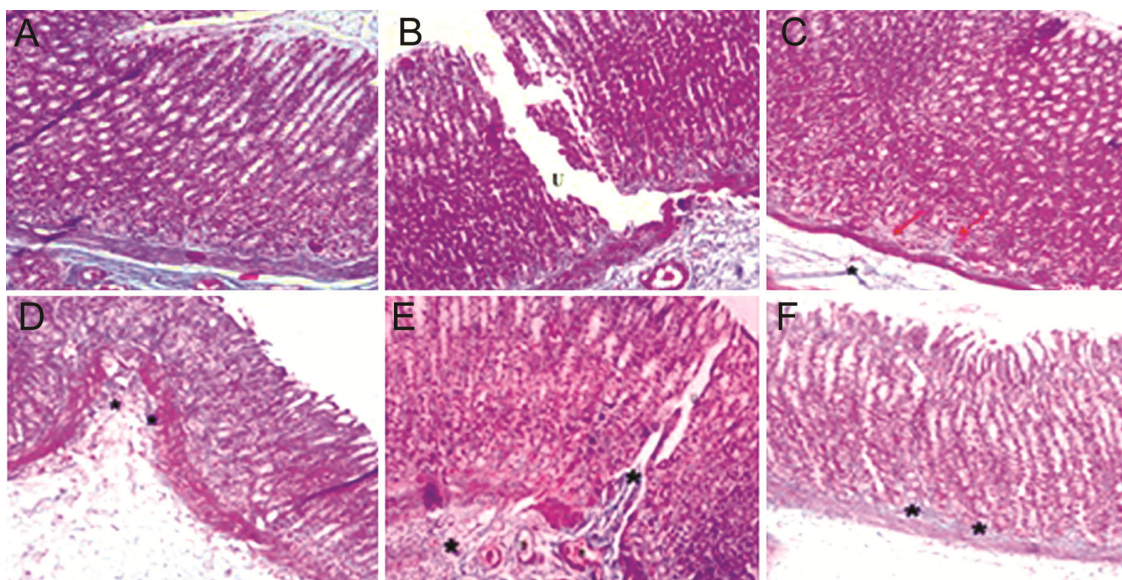


Fig. 3 — Histological section of gastric mucosa in pretreated group with: (A) LR-B-4-11, 50 mg/kg body wt.; (B) LR-B-4-11, 100 mg/kg body wt.; (C) LR-B-4-12, 50 mg/kg body wt.; (D) LR-B-4-12, 100 mg/kg body wt.; (E) indomethacin; and (F) DMSO (control group). [Each group was assessed at 400X magnification (H&E, scale bar=200 μ m); \rightarrow :clear boundaries, M: muscularis mucosa, BV: congested blood vessels in submucosa, L: loss of some cells in the basal part of the fundic gland, *: submucosal odema and U: gastric ulcer]

Discussion

Indomethacin, an NSAID, is a significant risk factor for gastric ulcers. It works principally by preventing the activity of cyclooxygenase enzyme, resulting in a reduction of prostaglandins synthesis²⁵. The use of NSAIDs could cause damage to gastric and duodenal mucosa through a diversity of mechanisms, for example, irritation of epithelium by these drugs, impairment of mucosal membrane barrier properties, inhibition of prostaglandins production, reduction of gastric mucosal blood flow, and interference with superficial injury repair²⁶. Prostaglandins typically impart cytoprotective influence on the mucosal layer, since they suppress hydrochloric acid and activate secretions of protective factors such as mucus and bicarbonate. The indomethacin-caused disturbance of the mucosal defense system lets gastric acid directly erode the mucosal layer²⁷.

The phytochemical examination of *L. racemosa* methanolic extract showed the presence of alkaloids, phenols, steroids, triterpenoids, flavonoids, and coumarins. Several studies have documented the protective effects of some terpenoids, steroids and phenolic compounds (tannins, coumarins and flavonoids) due to their antioxidant properties. Recently, a variety of natural products have been extensively explored and exposed to clinical trials to develop anti-inflammatory agents^{28,29}. The presence of major

phytoconstituents in the *n*-BuOH extract of leaves of *L. racemosa* makes it a promising candidate for promote the survey. The phytochemical study of LR-B-4-11 and LR-B-4-12 fractions led to the identification of 9 compounds; myricetin 3-*O*-methyl glucuronate, lumniracemoside, *n*-hexanol 1-*O*-rutinoside, 1,3,6-tri-*O*-galloyl- β -D-glucopyranose, corilagin, myricetrin, mixture of myricetin 3-*O*- β -D-glucopyranoside and myricetin 3-*O*- β -D-galactopyranoside, 1,2,3,4,6-penta-*O*-galloyl- β -D-glucopyranose, and quercetin 3-*O*-rutinoside¹⁷. These compounds play a very important role as antioxidant, antiulcer, and anti-inflammatory agents that could be the reason for the antiulcer activity of *L. racemosa* leaves extract.

Conclusion

The *n*-BuOH extract of *Lumnitzera racemosa* leaves showed protection against characteristic lesions caused by indomethacin administration. The dose of 50 mg/kg showed a higher level of cytoprotection. This antiulcer activity may have occurred due to the identified nine compounds. The antiulcerogenic effect of the extract may be due to the reduction of gastric acid secretion and gastric cytoprotection. However, the mechanisms behind these events are still unknown. Further studies are required to determine their precise mechanism of action on gastric acid secretion and gastric cytoprotection.

Conflict of interest

Authors declare no competing interests.

References

- 1 Mayty P, Biswas K, Roy S, Banerjee RK & Bandyopadhyay U, Smoking and pathogenesis of gastroduodenal ulcer-recent mechanistic update. *Mol Cell Biochem*, 253 (2003) 329.
- 2 Prados CMA & Miquel DB, Úlceras péptica. *Rev Esp Enferm Dig*, 96 (2004) 81.
- 3 Bandyopadhyay D, Biswas K, Bhattacharyya M, Reiter RJ & Banerjee RK, Gastric toxicity and mucosal ulceration induced by oxygen-derived reactive species, protection by melatonin. *Curr Mol Med*, 1 (2001) 501.
- 4 Bhattacharjee M, Bhattacharjee S, Gupta A & Banerjee RK, Critical role of an endogenous gastric peroxidase in controlling oxidative damage in *H. pylori*-mediated and non-mediated gastric ulcer. *Free Radical Biol Med*, 3 (2002) 731.
- 5 Konturek PC & Konturek S, Role of Helicobacter pylori infection in gastro-duodenal secretion and in pathogenesis of peptic ulcer and gastritis. *J Physiol Pharmacol*, 45 (1994) 333.
- 6 Wallace JL & Granger DN, The cellular and molecular basis of gastric mucosal defense. *FASEB J*, 10 (1996) 731.
- 7 Vimala G, Gricilda Shoba F, Pandikumar P & Sukumar E, Pharmacological evaluations of ethanol extract of *Ficus benghalensis* L. seeds for its antiulcer and antimicrobial efficacy. *Indian J Nat Prod Resour*, 8 (2017) 329.
- 8 Calam J & Baron JH, Pathophysiology of duodenal and gastric ulcer and gastric cancer. *Brit Med J*, 323 (2001) 980.
- 9 Liu C & Crawford JM, In: Robbins & Cotran: Pathologic Basis of Disease; (Ed. Kumar V, Abbas AK & Fausto N, Elsevier: Rio de Janeiro, Brazil), 2005, 851.
- 10 D'Souza L, Wahidulla S & Devi P, Antibacterial phenolics from the mangrove *Lumnitzera racemosa*. *Indian J Mar Sci*, 39 (2010) 294.
- 11 Yu SY, Wang SW, Hwang TL, Wei BL, Su CJ, Chang FR & Cheng YB, Components from the leaves and twigs of mangrove *Lumnitzera racemosa* with anti-angiogenic and anti-inflammatory effects. *Mar Drugs*, 16 (2018) 404.
- 12 Eswaraiyah G, Abraham Peele K, Krupanidhi S, Indira M, Bharath Kumar R & Venkateswarulu TC, GC-MS analysis for compound identification in leaf extract of *Lumnitzera racemosa* and evaluation of its *in vitro* anticancer effect against MCF7 and HeLa cell lines. *J King Saud Univ Sci*, 32 (2020) 780.
- 13 Anjaneyulu ASR, Murthy YLN, Rao VL & Sreedhar K, A new aromatic ester from the mangrove plant *Lumnitzera racemosa* Willd. *ARKIVOC*, 3 (2003) 25.
- 14 Lin TC, Hsu FL & Cheng JT, Antihypertensive activity of corilagin and chebulinic acid, tannins from *Lumnitzera racemosa*. *J Nat Prod*, 56 (1993) 629.
- 15 Ravikumar S & Gnanadesigan M, Hepatoprotective and antioxidant activity of a mangrove plant *Lumnitzera racemosa*. *Asian Pac J Trop Biomed*, 1 (2011) 348.
- 16 Thao NP, Luyen BTT, Diep CN, Tai BH, Kim EJ, Kang HK, Lee SH, Jang HD, Cuong NT, Thanh NV, Cuong NX, Nam NH, Minh CV & Kim YH, *In vitro* evaluation of the antioxidant and cytotoxic activities of constituents of the mangrove *Lumnitzera racemosa* Willd. *Arch Pharm Res*, 38 (2015) 446.
- 17 Darwish AGG, Samy MN, Sugimoto S, Otsuka H, Abdel-Salams H & Matsunami, K, Effects of hepatoprotective compounds from the leaves of *Lumnitzera racemosa* on acetaminophen-induced liver damage *in vitro*. *Chem Pharm Bull*, 64 (2016) 360.
- 18 Darwish AGG, Samy MN, Sugimoto S, Otsuka H, Abdel-Salam H, Issa MI, Shaker ES & Matsunami K, Bioactive compounds from the leaves of *Lumnitzera racemosa* against acetaminophen-induced liver damage *in vitro*. *J Arid Land Stud*, 26 (2016) 183.
- 19 Darwish AGG, Samy MN, Sugimoto S, Otsuka H & Matsunami K, A new macrolactone, racemolide along with seven known compounds with biological activities from mangrove plant, *Lumnitzera racemosa*. *Nat Prod Commun*, 14 (2019) 1.
- 20 Khattab MM, Gad MZ & Abdallah, D, Protective role of nitric oxide in indomethacin-induced gastric ulceration by a mechanism independent of gastric acid secretion. *Pharmacol Res*, 43 (2001) 463.
- 21 Sanyal A, Pandey B & Goel R, The effect of the traditional preparation of copper, *tamrabhasma* on experimental ulcers and gastric secretion. *J Ethnopharmacol*, 5 (1982) 79.
- 22 Dharmani P, Kuchibhotla V, Maurya R, Srivastava S, Sharma S & Palit G, Evaluation of anti-ulcerogenic and ulcer-healing properties of *Ocimum sanctum* Linn. *J Ethnopharmacol*, 93 (2004) 197.
- 23 Sener G, Paskaloglu K & Ayanoglu-dülger G, Protective effect of increasing doses of famotidine, omeprazole, lansoprazole, and melatonin against ethanol-induced gastric damage in rats. *Indian J Pharmacol*, 36 (2004) 171.
- 24 Bancroft J, Stevens A & Turner D, *Theory and Practice of Histological Techniques*. (Churchill Livingstone, New York/London/San Francisco/ Tokyo), 1996.
- 25 Hiruma-Lima, CA, Batista LM, de Almeida ABA, de Pietro LM, dos Santos LC, Vilegas W & Brito ARMS, Antiulcerogenic action of ethanolic extract of the resin from *Virola surinamensis* Warb. (Myristicaceae). *J Ethnopharmacol*, 122 (2009) 406.
- 26 Wallace L, How do NSAIDs cause ulcer disease?. *Best Pract Res Clin Gastroenterol*, 14 (2000) 147.
- 27 Ugwah MO, Ugwah-Oguejiofor CJ, Etuk EU, Bello SO & Aliero AA, Evaluation of the antiulcer activity of the aqueous stem bark extract of *Balanites aegyptiaca* L Delile in Wistar rats. *J Ethnopharmacol*, 239 (2019) 111931
- 28 Hong J, Smith TJ, Ho CT, August DA & Yang CS, Effects of purified green and black tea polyphenols on cyclooxygenase- and lipoxygenase-dependent metabolism of arachidonic acid in human colon mucosa and colon tumor tissues. *Biochem Pharmacol*, 9 (2001) 1175.
- 29 Gelen V & Şengül E, Antioxidant, anti-inflammatory and antiapoptotic effects of naringin on cardiac damage induced by cisplatin. *Indian J Tradit Knowl*, 19 (2020) 459.