Indian Journal of Experimental Biology
Vol. 64, September 2026, pp. 972- 979
DOI: 10.56042/ijeb.v64i10.23899

Nephroprotective effect of Astaxanthin in cisplatin-induced renal injury in a rat model

Özlem Coşkun[a*], Buket Güngör[b], Ender Tekeş[b]

[a]Department of Biophysics, Faculty of Medicine, Canakkale Onsekiz Mart University, Canakkale, 17020, Turkey.
[b]Department of Pharmacology, Faculty of Medicine, Canakkale Onsekiz Mart University, Canakkale, 17020, Turkey.

Received 17 September 2025; revised 20 March 2026

This study investigates the possible protective effects of astaxanthin (AX) against cisplatin (CP)-induced nephrotoxicity. The nephroprotective effect of AX against cisplatin-induced inflammation-induced renal injury was evaluated by biochemical and histopathologic analysis. Five groups were examined: saline control, DMSO carrier, AX (50 mg/kg/day, i.p., 7 days), CP (10 mg/kg, i.p.), and AX+ CP. Renal function (serum creatinine, BUN, and urinary KIM-1) and markers of inflammation (IL-1β, IL-6, TNF-α, NF-κB, and COX-2) were evaluated in kidney tissues using ELISA. Histopathologic changes were assessed using hematoxylin and eosin staining. It was determined that single-dose CP administration to rats increased BUN, Cr, and Kim-1 values and caused histopathologic renal toxicity in this group. AX treatment significantly reversed the acute renal injury caused by CP. A statistically significant increase in TNF-α, IL-6, IL-1β, COX-2, and NF-κB concentration levels was observed in the CP group ($p<0.05$). In contrast, a statistically significant decrease was observed in the AX-treated group ($p<0.05$). Notably, COX-2 and NF-κB levels were significantly elevated in the CP-treated group, while AX treatment effectively down-regulated these inflammatory markers. In addition, histopathologic examination revealed focal mononuclear cell infiltration areas in the CP-induced interstitial region, congestion areas in the interstitial region, degenerative changes and focal necrosis areas in tubular epithelial cells, enlargement of the bowman space, and hyperemia. Histopathologic examination showed that AX attenuated renal injury. The findings of the present study suggest that AX may provide new opportunities to understand its anti-inflammatory properties better and that the significant reduction of inflammatory cytokine levels in kidney tissue by AX may be related to its anti-inflammatory effect, thus suggesting that it may be a candidate therapeutic molecule against CP-induced nephrotoxicity. We recommend that the ability of AX to limit the increase of inflammatory mediators in kidney tissue may be promising for further clinical applications in protecting against CP-induced kidney injury or at least reducing its adverse effects.

Keywords: Cisplatin, Astaxanthin, Nephrotoxicity, Acute kidney injury, Inflammation, Cytokines

Introduction

Cisplatin (cis-diamminedichloroplatinum II, CP) is a first-generation platinum derivative that is highly effective in the treatment of many types of cancer such as testicular, oesophageal, pancreatic, gastric, and lung cancer. CP is the most widely used anticancer drug due to its therapeutic effect on cancer. Despite its widespread clinical use, CP is a cytotoxic agent. CP cytotoxicity is not limited to malignant cells; healthy cells have a higher uptake of cisplatin than cancer cells, making them more prone to damage. While CP-induced toxicities include ototoxicity, gastrotoxicity, hematological toxicity, and allergic reactions, the most common dose-limiting side effect of CP is nephrotoxicity. Nephrotoxicity increases with the dose, frequency of administration, and cumulative dose of CP [1]. Acute parenchymal damage develops with acute kidney injury and hydroelectrolytic disorders, especially due to tubular necrosis, proximal tubule degeneration, and infiltration of immune cells. Abrupt changes in renal function are characterized by decreased glomerular filtration rate (GFR), elevated serum creatinine (Cr) and blood urea nitrogen (BUN) levels, and increased oxidative stress. Many studies have shown that a single dose of CP increases urea, Cr, and BUN levels[2-5].

CP has been reported to have a complex pathophysiology associated with inflammation, apoptosis, and oxidative stress. However, the exact mechanism is still unclear. It has been reported that CP-induced inflammation is mediated by multiple mechanisms activating nuclear factor kappa-B (NF-κB), COX-2, and TNF-α[6-7].

*Corresponding author:
*e-mail: ozlemcoskun@comu.edu.tr

Currently, there is no effective drug or method against CP-induced kidney damage. Recent in vitro and in vivo studies have shown that many natural products (flavonoids, saponins, alkaloids, polysaccharides, phenylpropanoids, etc.) have specific antioxidant, anti-inflammatory, and anti-apoptotic properties that regulate pathways associated with CP-induced kidney injury[8].

AX is a red-orange carotenoid pigment found in aquatic animals such as salmon, crabs, and shrimp. Studies have reported the protective effects of AX on various diseases such as chronic kidney disease, neuroprotective, anti-inflammatory, and cardioprotective[9-11]. Due to its strong antioxidant properties, anti-inflammatory, anti-apoptotic, and immune modulation, AX is a multi-targeted pharmacological agent widely used as a dietary supplement and antioxidant[12-14].

In the literature, there are very few studies reporting the anti-inflammatory effect of AX against CP-induced kidney damage and its protective effect is still unknown. AX has been reported to increase immune response and decrease inflammation. Although the antioxidant effects of AX are well known, its anti-inflammatory role is still under investigation. Reactive oxygen species (ROS) and inflammation have been reported to be closely related. AX has been reported to exert anti-inflammatory effects by regulating oxidative stress/antioxidant levels. However, the specific mechanism of its anti-inflammatory effect has not yet been elucidated[15-18].

In the present study, we aimed to investigate the molecular mechanisms underlying CP-induced nephrotoxicity in a rat model both biochemically and histopathologically and to investigate the possible nephroprotective role of AX, which we proposed to prevent this toxicity, in terms of inflammation.

Materials & Methods

Animal Experiment In our study, adult male Wistar rats (n=40) weighing 200-250 g were obtained from Experimental Research Application and Research Centre. Approval was obtained from Animal Experiments Local Ethics Committee (Decision no: 2022/07-05). They were maintained in the laboratory under controlled environmental conditions (12-hour light/dark cycle) with free access to feed and water (ad libitum) for one week. Rats were randomly divided into 5 groups (n=8). 1) SF (saline): Intraperitoneal (i.p.) saline injection was performed. 2) Dimethyl sulphoxide (DMSO): 20% DMSO was administered (i.p.). 3) AX 50 mg /kg/day ip for 7 days. AX was dissolved in 20% DMSO. 4) CP was given i.p. as a single dose of 10 mg/kg CP. 5) CP + AX; AX (50 mg/kg/day, i.p. for 7 days)[19] On day 2, a single i.p. CP injection (10 mg/kg) was administered.

On day 6, rats were placed in metabolic cages for 24-hour urine collection. Urine was collected on day 7, immediately before sacrifice. On day 7, rats were anesthetized with xylazine (5 mg/kg) and ketamine (80 mg/kg) and then sacrificed. Blood samples were collected for serum analysis. Kidney samples were collected for histopathological examination.

Serum and urine samples were analyzed for blood urea nitrogen (OttoBC157; Otto Scientific), creatinine (OttoBC139; Otto Scientific), and Kim-1 (E0549Ra; BT-lab). IL-1β (E0119Ra, BT-lab), IL-6 ((ELK1158, Elabscience), TNF-α (E0764Ra, BT-lab), NF-κB (E-EL-R0673, Elabscience), COX-2 (E0296Ra, BT-lab) renal tissue levels were measured by ELISA method.

Histopathological Analysis (Hematoxylin & Eosin staining (H&E))

Kidney tissues were fixed in 10% buffered formaldehyde and processed using an automated tissue processor (TP 1020, Leica, Wetzlar, Germany). Paraffin-embedded tissues were sectioned (4 μm) and deparaffinized using a sliding microtome (SM 2010 R, Leica, Wetzlar, Germany). Sections were stained with hematoxylin and eosin, mounted with entellan and examined under a light microscope (Olympus BX43, DP22 digital camera). Histopathological scoring was performed on a scale of 0 (undetectable), 1 (mild), 2 (extensive), and 3 (severe) in 10 random fields at 200x magnification as described by Gibson-Corley et al.[20] Interstitial mononuclear cell infiltration, congestion, tubular epithelial degeneration/necrosis, Bowman's space enlargement, and hyperemia were quantified using ImageJ software (Version 1.53J, NIH, USA).

Chemicals

Urea (Bun), Creatinine, Interleukin 1 Beta (IL-1β), Interleukin 6 (IL-6), Kim-1 (Kidney Injury Molecule 1), Nuclear Factor Kappa B (NF-κB), Cyclooxygenase-2 (COX-2), TNF-α (Tumour Necrosis Factor Alpha) ELISA Kits, Histopathological Kit- Otto Scientific brand Astaxanthin (Sigma Aldrich), Cisplatin (Calbiochem), DMSO (Carlo Erba)

Statistical Analysis

SPSS version 19 was used for statistical evaluation of the data. Data were expressed as mean ± standard error of the mean and analyzed using one-way analysis of variance (ANOVA). The significance between the two groups was evaluated by the Dunnett

multiple comparison test and P value <0.05 was considered statistically significant. For the analysis of histopathological data, a non-parametric test for multiple comparisons (Kruskal-Wallis) was used. Differences were considered statistically significant if the P value was <0.05.

Results

During the one-week treatment period, the body weights of rats were monitored daily before injections. No significant weight change was observed between the groups from day zero to day seven. Similarly, no significant difference in kidney weights was observed in the groups at the time of euthanasia.

Blood urea nitrogen, serum creatinine, and Kim-1 levels were tested as biochemical markers for nephrotoxicity (Table 1). CP group significantly increased serum BUN (114.4±8.7), serum creatinine (2.0±0,01 mg/dl), and urinary Kim-1 (3.4±0.13) levels compared with the SF group (p<0.001, Figure 1).

No significant change was detected in BUN and serum creatinine levels in the AX group compared with the SF group. However, administration of AX in combination with CP resulted in a statistically

Table 1 — Mean± standard error of the mean± standard error of serum urea, creatinine and urinary KIM-1 levels in all groups.

Groups	Creatine (mg/dl) (mean ± std. error)	BUN (mg/dl) (mean ± std. error)	KIM-1 (mg/dl) (mean ± std. error)
SF	0,4±0,004	10,8±0,64	1,22±0,07
AX	0,5±0,007	15,8±0,66	1,16±0,60
DM	0,5±0,016	16,1±0,9	1,2±0,17
CP	2,0±0,01*#†‡	114,4±8,7*#†‡	3,4±0,13*#†‡
AX+CP	1,1±0,07	15,7±1,5	1,3±0,09

*p <0.05 vs. SF group;
#p <0.05 vs. AX group;
†p <0.05 vs. DM group;
‡p <0.05 vs. AX+CP group.

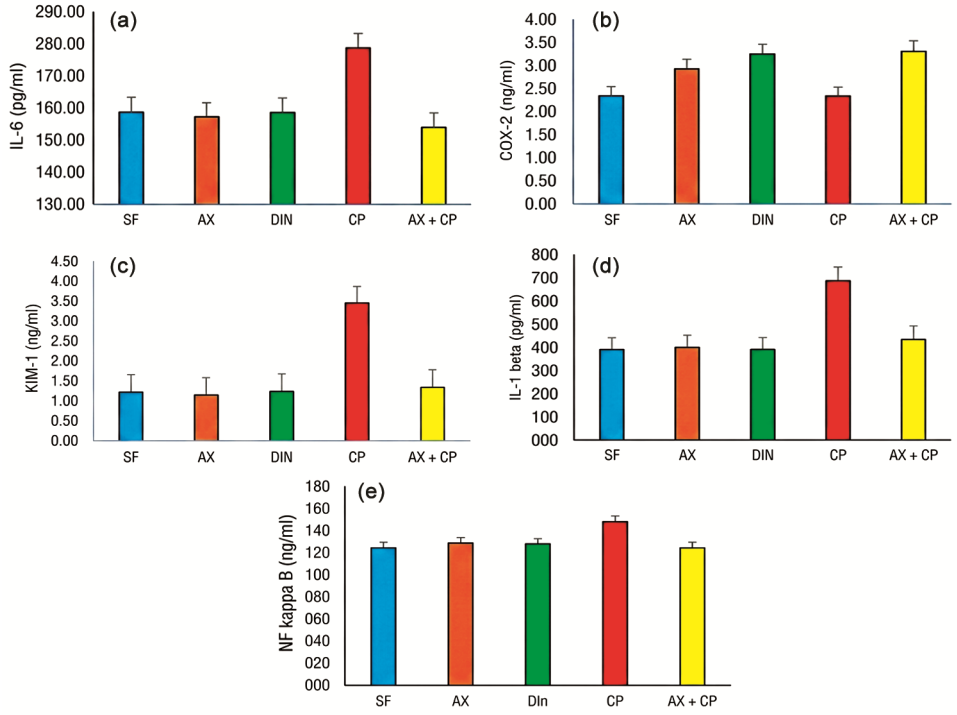

Fig. 1a — IL-6 levels in rat kidney tissue in each group. Values are given as the mean ± 1b- COX-2 levels in rat kidney tissue in each group. Values are given as mean ± standard error of the mean of 8 rats in each group. 1c- Administration of AX in combination with CP resulted in a statistically significant decrease in the increase in serum Cr and urinary KIM-1 levels compared with the control SF group (p <0.001) (Table 1). 1d- IL-1β levels in rat kidney tissue in each group. Values are given as mean ± standard error of the mean of 8 rats in each group. 1e- NF-κB levels in rat kidney tissue in each group. Values are given as mean ± standard error of the mean of 8 rats in each group.

significant decrease in the increase in serum Cr and urinary Kim-1 levels compared with the SF group ($p < 0.001$) (Table 1).

When the CP group was compared with the SF group, AX group, and DMSO group, IL-1β (6.88±0.43) level was significantly increased ($p<0.001$).

When the AX group was compared with the SF group, no significant change in IL-1β level was detected. However, when AX was administered in combination with CP, a statistically significant decrease in IL-1β level was detected when compared with the SF group ($p < 0.001$) (Table 1).

When the CP group was compared with the SF group, AX group, and DMSO group, the IL-6 level (278.40±2.59) increased significantly ($p<0.001$).

The AX group did not show a significant change in IL-6 level when compared with the SF group. However, when AX was administered in combination with CP, a statistically significant decrease in IL-6 level was found when compared with the SF group ($p < 0.001$) (Table 1).

Regarding the molecular inflammatory markers, COX-2 levels in the CP group were significantly increased compared to the SF group ($P < 0.001$). Administration of Astaxanthin (AX+CP group) significantly suppressed this increase, bringing COX-2 levels back toward control values ($P < 0.05$).

No change was found in COX-2 levels in the CP group compared with SF ($P=0.677$). A significant increase was observed in COX-2 levels of DMSO and AX+CP groups compared to the SF group ($P=0.002$; $P=0.001$, respectively).

CP group showed a significant increase in NF-κB levels compared to SF ($P=0.008$). AX+CP treatment resulted in a significant decrease in NF-κB levels compared with the CP group ($P=0.012$).

CP administration significantly increased IL-1β levels compared to all other groups (Table 2, Figure 2). When the effect of CP co-administration with AX on IL-1β levels was analyzed, it was determined that the increase was not significant compared to the group (Table 2, Figure 2).

It was observed that the CP group increased IL-6 levels statistically significantly compared to the other groups (SF, DMSO, and CP+AX). IL-6 levels were also increased in the AX-only group, but it was not found statistically significant because the standard deviation value was higher in the AX group (Table 2, Figure 3).

CP group significantly increased NF-κB levels compared to the AX group (n:8; 1.49±0.09; 1.24±0.04). NF-κB levels in the group in which cisplatin was administered alone were also found to

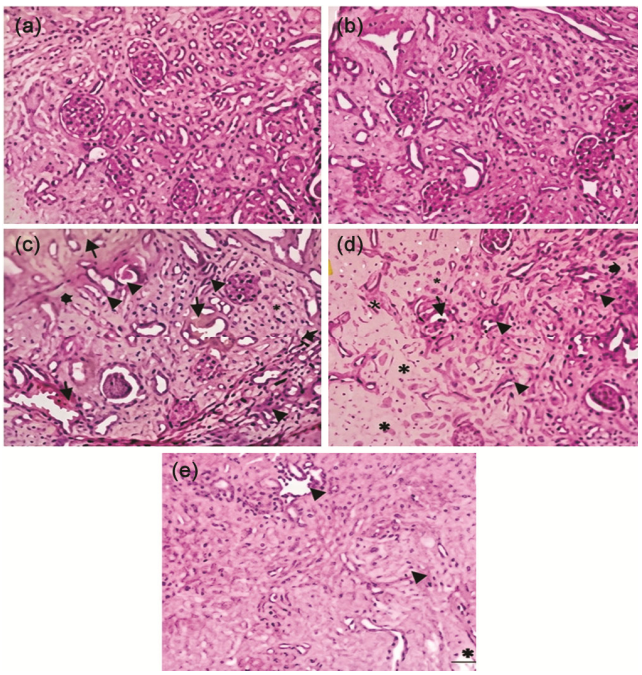

Fig. 2 — Histopathological evaluation graph of all groups in kidney tissue Micrographs of kidney sections. A: SF group; B: AX group; C: DM group; D: CP group; E: CP+AX group. Micrograph magnification is 200x and the scale shows 100 micrometers. Arrows indicate areas of congestion and hyperemia, arrowheads indicate degenerative regions, and thick arrows indicate areas of necrosis.

Table 2 — Evaluation of IL-1β, IL-6 and NF-κB levels of the groups

	IL-1β	**P**	**IL-6**	**P**	**COX-2**		**NF-κB**	**P**
SF	3,87±0,13*		258,47±7,9	0,029*	2,34±0,06		1,24±0,04	0,008*
AX	3,95±0,13**	0,000	256,92±15,44		2,93±0,20	0,016	1,28±0,05	
DM	3,88±014$^{\alpha}$		258,33±4,69	0,005$^{\alpha}$	3,24±0,02	0,000*	1,27±0,06	
CP	6,88±0,43		278,39±2,59		2,32±0,04		1,49±0,09	
AX + CP	4,36±0,40$^{\beta}$	0.007	25,83±12,32	0,025$^{\beta}$	3,29±0,18	0,0008	1,24±0,03	0,012$^{\beta}$

*P value when the control group is compared with the cisplatin group
**p value astaxanthin group was compared with cisplatin group
αp value when DMSO group was compared with cisplatin group
β CP+AST group compared with cispatin group, p value

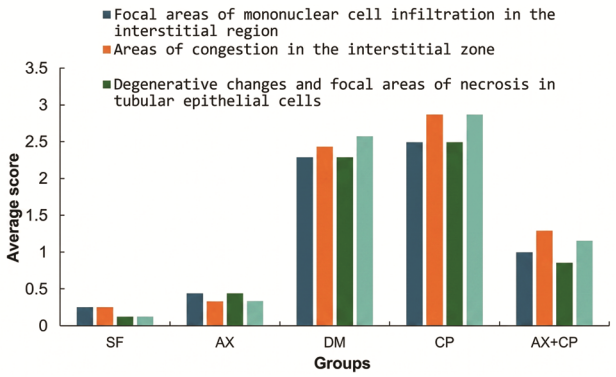

Fig. 3 — Histopathological scoring of kidney sections[50]. The graph quantifies the severity of various histopathological parameters, each represented by a different color, in response to different treatments.

be increased compared to the group in which AX was administered together with CP. There was no difference between the NF-κB levels of the AX+CP group and the SF group (Table 2, Figure 3).

Histopathological Analysis Results

In our study, histopathological kidney tissue samples were examined by Hematoxylin-Eosin (H&E) staining method. A natural histological structure was observed except for focal immune cell infiltrations and congestion in the interstitial space in a small amount in a very small portion of the sections belonging to the SF group. Similarly, although a natural histological structure was observed in the sections of the AX group, especially focal mononuclear cell infiltration in the interstitial region and tubular epithelial pathologies were slightly increased compared to the SF group ($p<0.05$). DMSO and CP groups showed a significant increase in all criteria ($p<0.001$). In the CP group, there was an increase in ecstasies and congestion in the Bowman's cavity compared to the DMSO group ($p<0.001$). Although the treatment group AX group had higher scores in all criteria compared to SF and KAX groups, it was superior to the CP group especially in terms of both congestion and necrosis ($p<0,001$). Considering these results, the nephroprotective feature of AX stands out prominently.

Discussion

The kidneys, primary organs for the excretion of drugs and toxic substances, are a significant target for drug-induced injury[21]. Consequently, drug-induced nephrotoxicity represents a major cause of clinical kidney damage[22]. CP stands as one of the most potent chemotherapeutic agents available; however, its clinical utility is often restricted by severe adverse effects, including ototoxicity, neurotoxicity, and most notably, nephrotoxicity. The pathophysiology of CP-induced damage involves a complex cascade of events such as oxidative stress, apoptosis, inflammation, and autophagy. These processes ultimately lead to necrosis in proximal tubule cells and vasoconstriction of the renal vascular architecture[23-26]. Despite the clear need for protective strategies, pharmacological interventions to prevent CP-induced cytotoxicity remain limited in clinical practice.

Standard reliable markers for determining renal dysfunction and drug-induced injury include serum BUN, Cr, and urinary Kim-1 levels[27-29]. Previous literature consistently reports significant elevations in these markers following CP exposure[30-33].In our study, we observed a clear increase in BUN and Cr levels in the CP group compared to the SF control, which correlated with the observed histopathological damage. Notably, treatment with AX successfully prevented the rise in serum BUN and Cr and led to a statistically significant decrease in urinary Kim-1 levels, indicating a robust preservation of renal function.

While the exact mechanism of CP nephrotoxicity is multifaceted, inflammation is widely recognized as a central driver of its pathophysiology. Pathological conditions trigger the release of soluble mediators, such as cytokines and chemokines, from activated or damaged kidney cells, which then recruit leukocytes to the site of injury[34]. Elevated levels of pro-inflammatory cytokines, including TNF-alpha, IL-1 beta, and IL-6 have been documented in cases of acute renal failure, with TNF-alpha playing a particularly critical role in pathogenesis[35].The molecular progression of this injury is often attributed to the production of ROS. The resulting increase in intracellular ROS in the kidney activates the transcription factor NF-kappa B[36-38]. Once activated, NF-kappa B mediates the inflammatory response by regulating the expression of key cytokines and enzymes, including TNF-alpha, IL-6, IL-1beta, and COX-2[39-44]. Consistent with these findings, our study observed significant increases in NF-kappa B, TNF-alpha, IL-6, and IL-1beta levels in CP-treated rats, a biochemical profile that aligned perfectly with our histopathological analysis.

Given the lack of effective drugs to treat CP-induced injury, natural products are being increasingly explored for their low toxicity and high efficacy [45,46]. While various carotenoids such as beta-carotene and lycopene have been investigated for their antioxidant properties, AX possesses unique structural

characteristics that render it a superior pharmacological agent. Unlike purely non-polar carotenoids like beta-carotene and lycopene, which are sequestered within the hydrophobic core of the cell membrane, the AX molecule contains polar hydroxyl and keto groups at both ends of its ionone rings. This amphiphilic structure allows AX to span the entire lipid bilayer, protecting both the inner hydrophobic region and the outer aqueous environment of the cell membrane. This transmembrane orientation significantly enhances its ability to quench singlet oxygen and scavenge free radicals compared to other carotenoids. Studies have indicated that the antioxidant activity of AX is approximately 10 to 100 times higher than that of beta-carotene and even 6,000 times more potent than Vitamin C. AX is a potent bioactive compound with documented antioxidant, anti-inflammatory, and immune-enhancing properties. Clinical and experimental models have confirmed its ability to alleviate both chronic and acute inflammation across various systems, including the gastrointestinal, nervous, and renal systems[47]. The fundamental mechanism underlying the reno-protective effects of AX is increasingly attributed to its ability to modulate the Nrf2 (Nuclear factor erythroid 2-related factor 2) signaling pathway. Nrf2 acts as a master regulator of the cellular antioxidant response. A key mechanism identified in our research is the modulation of the NF-kappa B, COX-2 axis. While COX-2 is typically expressed at low levels in healthy kidneys, it is significantly induced during inflammatory states under the regulation of NF-kappa[48].

The data regarding the molecular markers provide critical insights into the underlying inflammatory mechanisms. The induction of COX-2 by cisplatin is a key downstream event of NF-κB activation in renal tissues. Our results demonstrate that AX exerts its reno-protective effect by inhibiting the NF-κB/COX-2 signaling pathway, thereby reducing inflammatory cell infiltration and tubular damage.

In histopathological analysis, decreased Bowman's capsules and proximal and distal tubular areas were observed in CP + AX 75 mg groups compared to the CP group.

Our results showed that CP treatment increased IL-1β, IL-6, TNF-α, COX-2, and NF-κB activities in the kidney, whereas AX treatment decreased their activities. The decrease in TNF-α, IL-1β, and IL-6 levels after AX treatment supports the potential anti-inflammatory effect of AX.

In our study, histopathological analysis showed that CP administration caused significant damage in the kidneys including tubular necrosis, interstitial congestion, and proximal tubular loss (Figure 1).

Many studies have reported the protective role of AX in liver and kidney diseases. AX treatment has been reported to show anti-inflammatory and antioxidant effects with significant improvements in renal function parameters[49]. It has been reported that AX suppresses the expression of inflammatory factors including IL-1β, TNF-α, and NF-κB through modulation of the NF-κB signaling pathway[50].

Our present study showed that CP-injected rats significantly increased inflammatory markers. In contrast, concomitant treatment with AX significantly attenuated inflammation, showing a significant decrease in TNF-α, IL-1β, IL-6, and COX-2 levels. These findings indicated that AX may have possible nephroprotective effects as an anti-inflammatory drug.

Histopathological examination of kidney tissues confirmed the biochemical changes induced by the administered drug.

Although the antioxidant and anti-inflammatory benefits of AX are widely known, almost no studies have been conducted on CP-induced nephrotoxicity. Our study emphasizes the importance of AX's protective effect, especially against CP-induced nephrotoxicity.

Conclusion

CP exhibits a complex pathophysiology associated with inflammation, apoptosis, and oxidative stress; however, the exact molecular orchestrations remain to be fully elucidated. Recent evidence suggests that CP-induced inflammation is mediated by multiple pathways, including the activation of NF-κB, COX-2, and TNF-alpha.

The decrease in pro-inflammatory cytokines in AX-treated groups emphasizes its anti-inflammatory properties. These findings suggest that AX may effectively counteract CP-induced kidney injury and may offer a protective mechanism against the nephrotoxic effects of CP. We hope that AX will benefit new therapeutic research and clinical applications against CP-induced toxicity in the future. However, more detailed experiments are needed to elucidate its clinical efficacy to confirm the findings obtained in the studies.

In addition, our research integrates histopathological analyses to provide a holistic understanding of AX's potential to alleviate CP exposure-induced kidney

damage. This research contributes to the scientific literature by providing a targeted review of AX as a promising therapeutic agent against CP-induced nephrotoxicity. AX can be considered a possible candidate for its nephroprotective properties, especially in patients receiving cisplatin chemotherapy, but further studies are needed to confirm its efficacy and safety in humans.

Acknowledgements

This study has been funded by the Çanakkale Onsekiz Mart University Scientific Research Projects Coordination Unit (Project number TSA-2022-4220)

Ethical Approval

All procedures for experimental protocols of the present study involving animals were performed in accordance with the ethical standards of the institutions of practice at which the studies were conducted. (Ethical Committee Decision No:2022/07-05).

Availability of data and materials

The datasets used and/or analyzed during the study are available from the corresponding author upon reasonable request.

Conflicts of interest

The authors declare no conflicts of interest.

References

1 Galfetti E, Cerutti A, Ghielmini M, Zucca E & Wannesson L, Risk factors for renal toxicity after inpatient cisplatin administration. *BMC Pharmacology and Toxicology*, 21 (2020) 1.

2 Yilmaz Y, Tumkaya L, Mercantepe, T & Akyildiz K, Protective effect of astaxanthin against cisplatin-induced gastrointestinal toxicity in rats. *European Surgery*, 54 (2020) 1.

3 Bork T, Hernando-Erhard C, Liang W, Tian Z, Yamahara K & Huber TB, Cisplatin Nephrotoxicity Is Critically Mediated by the Availability of BECLIN1. *International Journal of Molecular Sciences,* 25 (2024) 2560.

4 Adelakun SA, Ogunlade B, Aniah JA, Akinyemi ON, Neuroprotective mechanisms and ameliorative activities of quercetin in cisplatin-induced cerebellum neurotoxicity in rat models. *Brain Disorders*, 16 (2024) 100166.

5 Ijaz MU, Ashraf A, Ahmed A, Ismail H, Muzzamil S, Samad A, Al-Ghanim KA, Al-Misned FA, Ahmed Z & Mahboob S, Remedial effects of casticin as an antioxidant on cisplatin induced oxidative damage in rat liver. *Journal of King Saud University-Science,* 32 (2020) 1100.

6 McSweeney KR, Gadanec LK, Qaradakhi T, Ali BA, Zulli A & Apostolopoulos V, Mechanisms of cisplatin-induced acute kidney injury: pathological mechanisms, pharmacological interventions, and genetic mitigations. *Cancers*, 13 (2021) 1572.

7 Holditch SJ, Brown CN, Lombardi AM, Nguyen KN & Edelstein CL, Recent advances in models, mechanisms, biomarkers, and interventions in cisplatin-induced acute kidney injury. *International journal of molecular sciences,* 20 (2019) 3011.

8 C Fang, D Lou, L Zhou, J Wang, B Yang, Q He, J Wang & Q Weng, Natural products: potential treatments for cisplatin-induced nephrotoxicity. *Acta Pharmacologica Sinica,* 42 (2021) 1951.

9 Terzi S, Ozgur A, Çeliker M, Mercantepe T, Yilmaz A, Tümkaya L, Kaya Ş & Demir E Dursun E, The protective effect of astaxanthin on cisplatin-induced ototoxicity. *Advances in Clinical and Experimental Medicine,* 30 (2021) 315.

10 Soliman MM, Alotaibi KS, Albattal SB, Althobaiti S, Al-Harthi HF & Mehmood A, Ameliorative impacts of astaxanthin against atrazine-induced renal toxicity through the modulation of ionic homeostasis and Nrf2 signaling pathways in mice. *Toxicology Research,*13 (2024) tfae071.

11 Guo S, Guo L, Fang Q, Yu M, Zhang L, You C, Wang X, Liu Y & Han C, Astaxanthin protects against early acute kidney injury in severely burned rats by inactivating the TLR4/MyD88/NF-κB axis and upregulating heme oxygenase-1. *Scientific Reports*; 11 (2021) 6679.

12 Choi HD, Kim JH, Chang MJ, Kyu-Youn, Y & Shin WG, Effects of astaxanthin on oxidative stress in overweight and obese adults. Phytotherapy Research, 25 (2011) 1813.

13 Chen Y, Li D, Lu W, Xing J, Hui B & Han Y, Screening and characterization of astaxanthin-hyperproducing mutants of Haematococcus pluvialis. *Biotechnology letters,* 25 (2003) 527.

14 Fakhri S, Yosifova Aneva I, Farzaei MH & Sobarzo-Sánchez E, The neuroprotective effects of astaxanthin: therapeutic targets and clinical perspective. *Molecules*, 24 (2019) 2640.

15 Chang MX & Xiong F, Astaxanthin and its effects in inflammatory responses and inflammation-associated diseases: recent advances and future directions. *Molecules,* 25 (2020) 5342.

16 Zhuang J, Zhou X, Liu T, Zhang S & Yuan F, Astaxanthin attenuated hyperuricemia and kidney inflammation by inhibiting uric acid synthesis and the NF-κ B/NLRP3 signaling pathways in potassium oxonate and hypoxanthine-induced hyperuricemia mice. *Die Pharmazie-An International Journal of Pharmaceutical Sciences,* 76 (2021) 551-558.

17 Miyachi M, Matsuno T, Miyazawa A, Asano K & Mataga I, Anti-inflammation response of astaxanthin on inhibiting nuclear factor kappa B activation. *Journal of Oral and Maxillofacial Surgery*, 72 (2014) e188.

18 Akca G, Eren H, Tumkaya L, Mercantepe T & Horsanali MO, The protective effect of astaxanthin against cisplatin-induced nephrotoxicity in rats. *Biomedicine& pharmacotherapy,* 100 (2018) 575.

19 Wu H, Niu H, Shao A, Wu, C, Dixon BJ, Zhang J & Wang Y, Astaxanthin as a potential neuroprotective agent for neurological diseases. *Marine drugs*, 13 (2015) 5750.

20 Gibson-Corley KN, Olivier AK & Meyerholz DK, Principles for valid histopathologic scoring in research. *Veterinary pathology*, 50 (2013) 1007.

21 Radi ZA, Kidney pathophysiology, toxicology, and drug-induced injury in drug development. *International journal of toxicology,* 38 (2019) 215.

22 Sales GTM & Foresto RD, Drug-induced nephrotoxicity. *Revista da Associação Médica Brasileira,* 66 (2020) s82. https://doi.org/10.1590/1806-9282.66.s1.82

23 Karagöl N, Cisplatin Nefrotoxicity and Treatment Approaches. *International Journal of PharmATA,* 3 (2023) 14.

24 Dobrek L, A synopsis of current theories on drug-induced nephrotoxicity. *Life*, 3 (2023) 325.

25 Oh GS, Kim HJ, Shen A, Lee SB, Khadka D, Pandit A & So HS, Cisplatin-induced kidney dysfunction and perspectives on improving treatment strategies. *Electrolytes & Blood Pressure: E & BP*, 12 (2014) 55.

26 Džidić-Krivić A, Sher EK, Kusturica J, Farhat EK, Nawaz, A & Sher F, Unveiling drug induced nephrotoxicity using novel biomarkers and cutting-edge preventive strategies. *Chemico-Biological Interactions,* 25 (2023) 110838.

27 Easmin S, Bhattacharyya M, Pal K, Das P, Sahu R, Nandi G, Paul P & Dua TK, Role of probiotics in the management of cisplatin-induced nephrotoxicity. *Medicine in Microecology*, 19 (2024) 100099.

28 Volarevic V, Djokovic B, Jankovic MG, Harrell CR, Fellabaum C, Djonov V, Arsenijevic N, Molecular mechanisms of cisplatin-induced nephrotoxicity: a balance on the knife edge between renoprotection and tumor toxicity. *Journal of biomedical science,* 26 (2019) 1.

29 Khairnar SI, Kulkarni YA & Singh K, Mitigation of cisplatin-induced nephrotoxicity by chelidonic acid in Wistar rats. *Journal of Trace Elements in Medicine and Biology,* 81 (2024) 127321.

30 Jana S, Mitra P, Dutta A, Khatun A, Das TK, Pradhan S, Nandi DK & Roy S, Early diagnostic biomarkers for acute kidney injury using cisplatin-induced nephrotoxicity in rat model. *Current Research in Toxicology,* 5 (2023) 100135.

31 Zhu X, Jiang X, Li A, Zhao Z, & Li S, S-Allylmercaptocysteine attenuates cisplatin-induced nephrotoxicity through suppression of apoptosis, oxidative stress, and inflammation. *Nutrients*, 9 (2017) 166.

32 Al-Naimi MS, Rasheed HA, Hussien NR, Al-Kuraishy HM & Al-Gareeb AI, Nephrotoxicity: Role and significance of renal biomarkers in the early detection of acute renal injury. *Journal of advanced pharmaceutical technology & research,* 10 (2019) 95.

33 Tang C, Livingston MJ, Safirstein R & Dong Z. Cisplatin nephrotoxicity: new insights and therapeutic implications. *Nature Reviews Nephrology*, 19 (2023) 53.

34 Miller RP, Tadagavadi RK, Ramesh G & Reeves WB, Mechanisms of cisplatin nephrotoxicity. *Toxins*, 2 (2010) 2490.

35 Pabla N, Dong Z, Cisplatin nephrotoxicity: mechanisms and renoprotective strategies. *Kidney international,* 73 (2008) 994.

36 Altındağ F, Silymarin ameliorates cisplatin-induced nephrotoxicity by downregulating TNF-α and NF-kB and by upregulating IL-10. *Journal of Experimental and Clinical Medicine,* 39 (2022) 216.

37 Lee JE, Kim JY & Leem J, Efficacy of Trametinib in Alleviating Cisplatin-Induced Acute Kidney Injury: Inhibition of Inflammation, Oxidative Stress, and Tubular Cell Death in a Mouse Model. *Molecules,* 29 (2024) 2881.

38 Wang H, Xia W, Long G, Pei Z, Li Y, Wu, M, Wang Q, Zhang Y, Jia Z & Chen H, Isoquercitrin ameliorates cisplatin-induced nephrotoxicity via the inhibition of apoptosis, inflammation, and oxidative stress. Frontiers in pharmacology, 11 (2020) 599416.

39 Ma N, Wei W, Fan X & Ci X, Farrerol attenuates cisplatin-induced nephrotoxicity by inhibiting the reactive oxygen species-mediated oxidation, inflammation, and apoptotic signaling pathways. *Frontiers in physiology*, 10 (2019) 1419.

40 Dilek ME, Gurel A, Dogantekin A, Sahin K, Ozercan IH, Ilhan N & Celiker H, Effects of Sesamol on Experimental Cisplatin Nephrotoxicity Model. *Kafkas Journal of Medical Sciences,* 10 (2020) 180.

41 Zhou J, Nie RC, Yin YX, Cai XX, Xie D & Cai MY, Protective Effect of Natural Antioxidants on Reducing Cisplatin-Induced Nephrotoxicity. *Disease markers,* 2022 (2022) 1612348.

42 Zhao H, Wu L, Yan G, Chen Y, Zhou M, Wu Y & Li Y, Inflammation and tumor progression: signaling pathways and targeted intervention. *Signal transduction and targeted therapy*, 6 (2021) 263.

43 Kumar P, Sulakhiya K, Barua CC & Mundhe N, TNF-α, IL-6 and IL-10 expressions, responsible for disparity in action of curcumin against cisplatin-induced nephrotoxicity in rats. *Molecular and cellular biochemistry,* 431 (2017) 113.

44 Farrokh-Eslamlou N, Momtaz S, Niknejad A, Hosseini Y, Mahdaviani P, Ghasemnejad-Berenji M & Abdolghaffari AH, Empagliflozin protective effects against cisplatin-induced acute nephrotoxicity by interfering with oxidative stress and inflammation in Wistar rats. Naunyn-Schmiedeberg's Archives of Pharmacology, 397 (2024) 7061.

45 Faubel S, Lewis EC, Reznikov L, Ljubanovic D, Hoke TS, Somerset H, Oh DJ, Lu L, Klein CL, Dinarello CA & Edelstein CL, Cisplatin-induced acute renal failure is associated with an increase in the cytokines interleukin (IL)-1β, IL-18, IL-6, and neutrophil infiltration in the kidney. *Journal of Pharmacology and Experimental Therapeutics,* 322 (2007) 8.

46 Oliyaei N, Moosavi-Nasab M, Tanideh N & Iraji A, Multiple roles of fucoxanthin and astaxanthin against Alzheimer's disease: Their pharmacological potential and therapeutic insights. *Brain Research Bulletin,* 193 (2023) 11.

47 Renaldi K, Simadibrata M, Rahadiani N, Handjari DR, Harahap AR, Harimurti K, Zubir N, Siregar L, Loho IM, Suzanna E, Prawirodihardjo B, Hidajat H, Widodo B, Rahniayu A, Tambun R, William A & Makmun D, The Expressions of NF− κB, COX− 2, Sp1, and c−Jun in Pancreatic Ductal Adenocarcinoma and Their Associations with Patient Survival. *Pathophysiology,* 30 (2023) 92.

48 Erkılınç G, Bedir M, Ayözger LEÖ, Doğan HK & Karakuyu NF, Nephroprotective Effect of Astaxanthin Against Radiotherapy Via TAS, TOS (Biochemical), TNF-α, CASPASE-3 (Immunohistochemical), SIRT 1-P53 (Molecular) Pathway in Rats. *Genel Tıp Dergisi*, 33 (2023) 14.

49 Crupi P, Faienza MF, Naeem MY, Corbo F, Clodoveo ML & Muraglia M, Overview of the potential beneficial effects of carotenoids on consumer health and well-being. *Antioxidants,* 12 (2023) 1069.

50 Davinelli S, Saso L, D'Angeli F, Calabrese V, Intrieri M & Scapagnini G, Astaxanthin as a modulator of Nrf2, NF-κB, and their crosstalk: molecular mechanisms and possible clinical applications. *Molecules,* 27 (2022) 502.