

Withania somnifera (L.) Dunal ameliorates imidacloprid induced neurotoxicity: Inhibition of oxidative stress, apoptosis and downregulation of glial fibrillary acidic protein in female Wistar rats

S Soujanya^{1*}, M Lakshman¹, D Madhuri³, A Gopala Reddy² & SV Rama Rao⁴

¹Department of Veterinary Pathology; ²Department of Veterinary Pharmacology and Toxicology, College of Veterinary Science, Rajendranagar, P V Narsimha Rao Telangana Veterinary University (PVNRTVU), Hyderabad-500 030, Telangana, India

³Department of Veterinary Pathology, College of Veterinary Science, Korutla, PVNRTVU, Jagtial-505 326, Telangana, India

⁴Department of Avian Nutrition, Directorate of Poultry Research, Rajendranagar, Hyderabad-500 030, Telangana, India

Received 27 May 2023; revised 21 October 2023

In agricultural farming, neonicotinoid insecticides are used to control insect pests on agricultural crops and ectoparasitic arthropods on animals. Here, we evaluated the oral toxicity of one of the commonly used neonicotinoid insecticides, imidacloprid (IMI) on the brain tissue of female Wistar rats and its amelioration by Indian ginseng, *Withania somnifera* (L.) Dunal. The study was conducted on a total of 48 female Wistar rats divided into four groups, each containing 12 rats. Gr. I was normal control; Gr. II, imidacloprid; Gr. III, *W. somnifera*; and Gr. IV with both imidacloprid and *W. somnifera*. The rats were subjected to oral treatment of *W. somnifera* (1 g/kg feed) for a period of 30 days to measure the protective effect against neurotoxicity induced by imidacloprid (30 mg/kg body wt./day). Six rats from each group were sacrificed on 16th and 31st day. The results showed that imidacloprid significantly decreased the reduced glutathione, super oxide dismutase and increased the thio barbituric acid reactive substance (TBARS) levels. It also caused histopathological, immunohistochemical and ultrastructural changes in the brain. Whereas, *W. somnifera* significantly increased the reduced glutathione, super oxide dismutase (SOD) and reduced the TBARS levels. Further, it inhibited apoptosis by upregulation of B-cell lymphoma 2 protein and reduced the neuronal degeneration by downregulation of glial fibrillary acidic protein. These results indicate that *Withania somnifera* may be beneficial in ameliorating the imidacloprid induced oxidative stress and apoptosis in the brain tissue of rats.

Keywords: Ashwagandha, B-cell lymphoma 2, Brain, Glial fibrillary acidic protein (GFAP) expression, Imidacloprid, Indian ginseng, Neonicotinoids, Neuroprotective, Winter cherry

Neonicotinoids are the most widely used newer class of insecticides due to its lower mammalian toxicity and highly selective insecticidal activity. These are broad spectrum and systemic insecticides with rapid action. Imidacloprid (IMI) is the first registered neonicotinoid insecticide used to control insect pests on agricultural crops and ectoparasitic arthropods on animals. It acts as a potent agonist on insect nicotinic acetylcholine receptors (nAChRs), specifically at the α -subunits of the nicotinic receptors¹.

Withania somnifera (L.) Dunal (Fam. Solanaceae), commonly called Ashwagandha, Indian ginseng or Winter cherry, is a potential medicinal Indian herb used in ayurveda for treatment of various ailments². The plant extract has many bioactive compounds and

thereby exerts antioxidant, immunomodulatory, antiaging, anticancer, anti-inflammatory and antistress activities. Dry leaf powder of *W. somnifera* has anxiolytic and anti-neuroinflammatory potential³.

In this study, we evaluated the oral toxicity of imidacloprid (IMI) on the brain tissue of female Wistar rats and its amelioration by *Withania somnifera*.

Material and Methods

Experimental animals

In the present study, 48 female albino rats (Wistar strain) weighing 200-250 g were procured from Sanzyme Private Limited (Pvt. Ltd.), Gagan Pahad, Hyderabad. The rats were housed in solid bottom polypropylene cages at lab animal house, College of Veterinary Science, Rajendranagar, Hyderabad and were maintained in controlled environment (20-22°C) throughout the course of the experiment. Sterile rice husk was used as a bedding material. All the rats were

*Correspondence:

Phone: +91 8919791759 (Mob.)

E-Mail: sonurv36@gmail.com

provided with standard pellet diet (procured from Vyas Labs, Uppal, Hyderabad) and deionized water *ad libitum* throughout the experimental period. All the experimental animals were observed thrice daily for clinical signs and mortality, if any, during the entire period of study. The experiment was conducted according to the guidelines and with prior approval of the Institutional Animal Ethics Committee (IAEC- No.7/22/C.V.Sc., Hyd. /IAEC).

Experimental design

The female Wistar rats were divided into four groups each comprising 12 rats. The group details are as follows: Gr. I, Control; Gr. II, imidacloprid @30 mg/kg body wt. orally; Gr. III, *Withania somnifera* @1 g/kg feed; and Gr. IV, imidacloprid @30 mg/kg body wt. orally + *W. somnifera* @1 g/kg feed.

Necropsy observations

Six rats from each group were sacrificed on 16th day and remaining were sacrificed on 31st day of the experiment by cervical dislocation a day after collection of blood and detailed postmortem examination was carried out as per standard procedure as suggested by Feinstein⁴. Gross lesions, if any, were recorded in brain.

Relative organ weight

Soon after sacrifice, individual weight of brain of all the rats were recorded using electronic balance to study the relative organ weight. Relative organ weight was expressed as per cent (%) of body weight in relation to body weight.

$$\text{Relative brain weight} = \frac{\text{Brain weight}}{\text{Body weight}} \times 100$$

Oxidative stress parameters

Oxidative stress parameters like reduced glutathione (GSH), the reaction of the lipid peroxidation end products like malondialdehyde (MDA) with thiobarbituric acid reactive substances (TBARS) and activity of superoxide dismutase (SOD) were estimated in brain according to the procedure described earlier⁵⁻⁷.

Histopathology

The brain tissues samples were collected and fixed in 10% neutral buffered formalin (NBF) soon after necropsy. The samples were processed, sectioned (5 µm) and stained with Hematoxylin and Eosin (H&E) for histopathological examination as per the standard procedure⁸.

Immunohistochemistry

Immunohistochemical analysis of B-cell lymphoma 2 (Bcl-2) protein in brain tissue was done according to the standard procedure described by Van Noorden⁹. Glial fibrillary acidic protein (GFAP) expression in brain tissue was estimated by avidin-biotin-peroxidase complex staining method¹⁰.

Ultrastructural pathology

The samples of brain tissue were collected and preserved in 2.5% gluteraldehyde (PBS based EM grade) and processed for transmission electron microscopy (TEM) and scanning electron microscopy (SEM) as per the standard protocol.

Statistical analysis

The data obtained were subjected to statistical analysis by applying one way ANOVA using Statistical Package for Social Sciences (SPSS) version 16.0. Differences between the means was tested by using Duncan's multiple comparison test and significance level was set at $P < 0.05$ ¹¹.

Results

Gross pathology

Mild congestion of brain was noticed in rats belonging to Gr. II on day 31 and no significant gross changes were recorded in brain of rats in groups I, III and IV.

Relative brain weight (% of body weight)

Group II rats showed significantly ($P < 0.05$) decreased mean values of relative brain weights (% of body wt.) when compared with Gr. I on 16th and 31st day of experiment. There was no significant difference in mean values of relative brain weights between groups I, III on 16th and 31st day of experiment (Table 1).

Table 1 — Relative brain weight, reduced glutathione concentration and superoxide dismutase activity in different groups

Groups	Relative brain weight (% of body wt.)		Glutathione (nmol/mg protein)		SOD activity (U/mg protein)	
	Day 16	Day 31	Day 16	Day 31	Day 16	Day 31
Gr. I	0.85±0.07 ^a	0.81±0.02 ^a	34.73±0.77 ^a	34.53±0.76 ^a	9.62±0.38 ^a	9.17±0.35 ^a
Gr. II	0.65±0.03 ^b	0.57±0.04 ^b	19.97±0.56 ^c	18.68±0.32 ^c	7.02±0.22 ^c	6.35±0.30 ^c
Gr. III	0.84±0.05 ^a	0.82±0.05 ^a	34.80±0.39 ^a	34.98±0.40 ^a	9.53±0.40 ^a	9.07±0.36 ^a
Gr. IV	0.83±0.04 ^a	0.78±0.06 ^a	29.47±0.46 ^b	27.55±0.45 ^b	8.23±0.47 ^b	8.05±0.29 ^b

[Gr. I Control; Gr. II, imidacloprid @30 mg/kg body wt orally; Gr. III, *Withania somnifera* @1g/kg feed; and Gr. IV, imidacloprid @30 mg/kg body wt orally+ *Withania somnifera* @1g/kg feed. Values are Mean + SE (n = 6); One way ANOVA. Means with different superscripts in a column differ significantly at $P < 0.05$]

Tissue antioxidant profile

Reduced glutathione concentration: GSH (nmol/mg protein)

The mean values of GSH concentrations in brain were significantly ($P < 0.05$) low in Gr. II and Gr. IV when compared with Gr. I and Gr. III on 16th and 31st day of experiment. The mean value of GSH concentration in brain was significantly ($P < 0.05$) high in Gr. IV when compared with Gr. II and there was no significant difference between groups 1 and 3 (Table 1).

Superoxide dismutase activity: SOD (U/mg protein)

The mean value of SOD activity in brain was significantly ($P < 0.05$) low in Gr. II and Gr. IV when compared with Gr. I and Gr. III on 16th and 31st day of experiment. The mean value of SOD activity in brain was significantly ($P < 0.05$) high in Gr. IV when compared with Gr. II and there was no significant difference between groups 1 and 3 (Table 1).

Thiobarbituric acid reactive substance concentration: (TBARS) (nmol MDA/mg protein)

The mean values of TBARS concentrations (nmol MDA/mg protein) in brain tissue in Gr. II and Gr. IV were significantly ($P < 0.05$) increased when compared with Gr. I and Gr. III on 16th and 31st day of experiment. In Gr. IV, a significant ($P < 0.05$) decrease in brain TBARS were recorded in comparison to Gr. II and Gr. III values were insignificant from control (Table 2).

Histopathology

The sections of brain from Gr. II rats on 16th day of experiment revealed severe congestion, moderate dilatation of blood vessels and focal gliosis in cerebral cortex. Moderate vacuolation and pyknotic pyramidal cells in hippocampus and moderate degeneration of Purkinje cells in cerebellum (Fig. 1(A-F)) was observed. On 31st day, brain sections showed perivascular haemorrhage, diffuse gliosis, neurophil vacuolation, focal necrosis of nerve cell bodies, shrunken and pyknotic neurons in cerebral cortex. Severe vacuolation and degenerated pyramidal cells with vesicular nuclei were noticed in hippocampus. Severe congestion, degenerative changes in granular layer, Purkinje cells with loss of dendrites and vacuolation around Purkinje cells were observed in cerebellum [Fig. 2 (A-G)].

Brain sections from Gr. IV rats revealed mild congestion of blood vessels in cerebral cortex, mild vacuolation in hippocampus and mild congestion in

Table 2 — Thiobarbituric acid reactive substance concentration (nmol MDA/mg protein) in brain in different groups

Groups	Day 16	Day 31
Gr. I	23.27 ± 0.45 ^c	24.25 ± 0.52 ^c
Gr. II	38.52 ± 0.43 ^a	40.05 ± 0.66 ^a
Gr. III	23.85 ± 0.60 ^c	24.67 ± 0.54 ^c
Gr. IV	29.43 ± 0.61 ^b	30.33 ± 0.53 ^b

[Values are Mean + SE (n = 6); One way ANOVA. Means with different superscripts in a column differ significantly at $P < 0.05$]

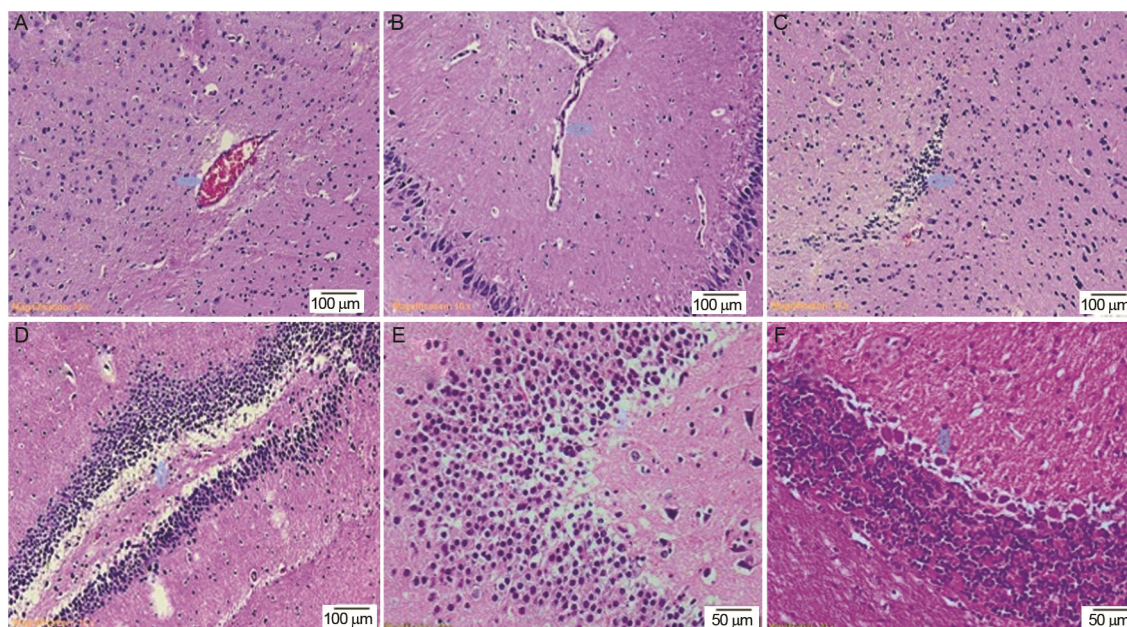


Fig. 1 — (A-F): Photomicrograph of brain showing (A) severe congestion (arrow), (b) moderate dilatation of blood vessels (arrow), (C) focal gliosis (arrow) in cerebral cortex, (D) moderate vacuolation in hippocampus (arrow) H&E x100; (E). moderate vacuolation (arrow) and pyknotic pyramidal cells in hippocampus and (F) moderate degeneration of Purkinje cells in cerebellum (arrow) H&E x200 (Gr. II, Day 16)

cerebellum on 16th day of experiment. In addition to vacuolation, degeneration of pyramidal cells in hippocampus and Purkinje cells in cerebellum [Fig. 3 (A-E)] were noticed on 31st day of experiment.

Immunohistochemistry

Brain sections from Gr. I and I revealed positive immunoreactivity for glial fibrillary acidic protein (GFAP) in cerebral cortex. Sections from Gr. II

showed marked increase and Gr. IV showed moderate increase in expression of GFAP in cerebral cortex (Fig. 4A).

Brain sections from Gr. I and III revealed intense strong positive immunoreactivity for Bcl-2 protein. Sections from Gr. II showed marked reduction and Gr. IV showed moderate reduction in immunostaining for Bcl-2 protein in cerebral cortex (Fig. 4B).

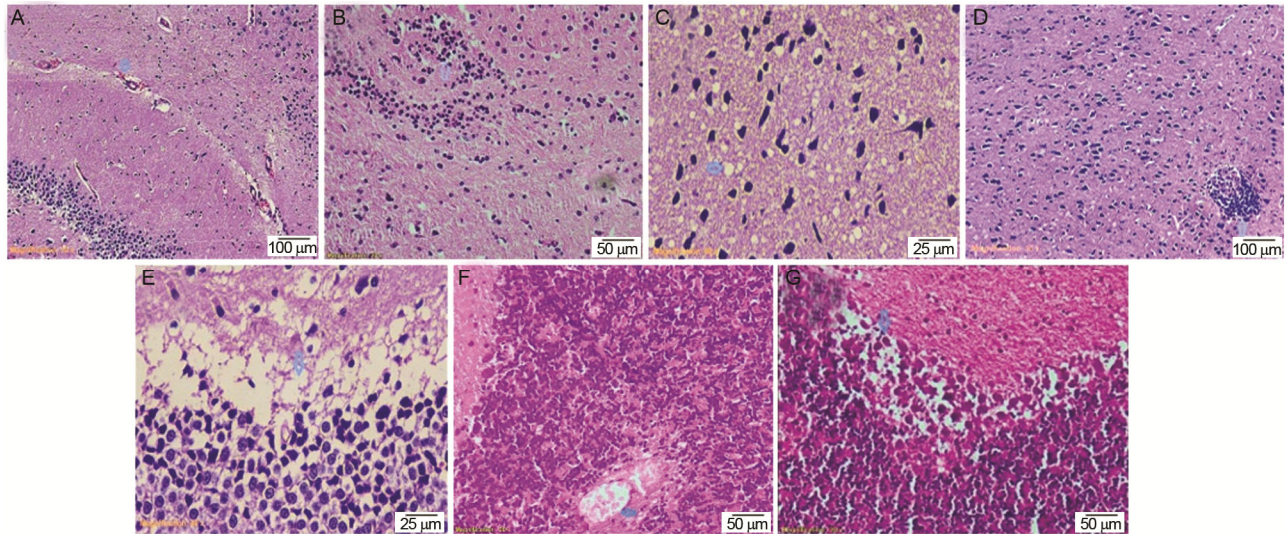


Fig. 2 — Photomicrograph of brain showing (A) perivascular haemorrhage (arrow) H&E 100X; (B) diffuse gliosis (arrow) H&E 200X; (C) vacuolation in neurophil (arrow) and shrinkage of neurons H&E 400X; (D) focal necrosis of nerve cell bodies (arrow) and pyknotic neurons in cerebral cortex H&E 100X; (E) severe vacuolation (arrow) and degenerated pyramidal cells with vesicular nuclei in hippocampus H&E 400X; (F) severe congestion (arrow) and degenerative changes in granular layer; and (G) severe degeneration of Purkinje cells with loss of dendrites (arrow) and vacuolation around Purkinje cells in cerebellum H&E 200X (Gr. II, Day 31)

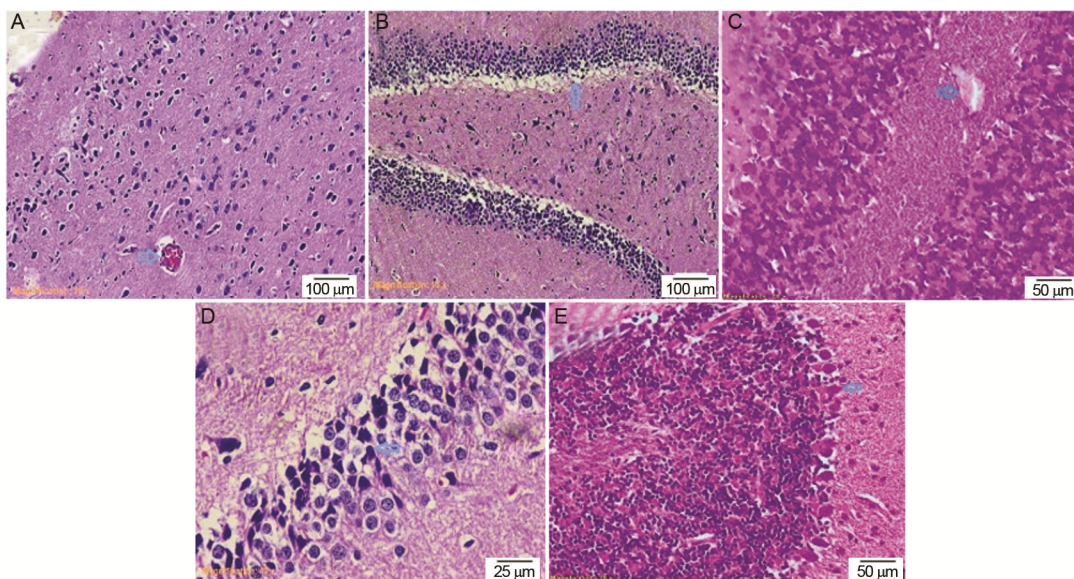


Fig. 3 — Photomicrograph of brain showing (A) mild congestion in cerebral cortex (arrow); (B) mild vacuolation in hippocampus (arrow) H&E 100 X; (C) mild congestion in cerebellum (arrow) H&E 200X (Gr. IV, Day 16); (D) mild vacuolation and degeneration of pyramidal cells in hippocampus (arrow) H&E 400X; and (E) mild degeneration of Purkinje cells in cerebellum (arrow) H&E 200X (Gr. IV, Day 31).

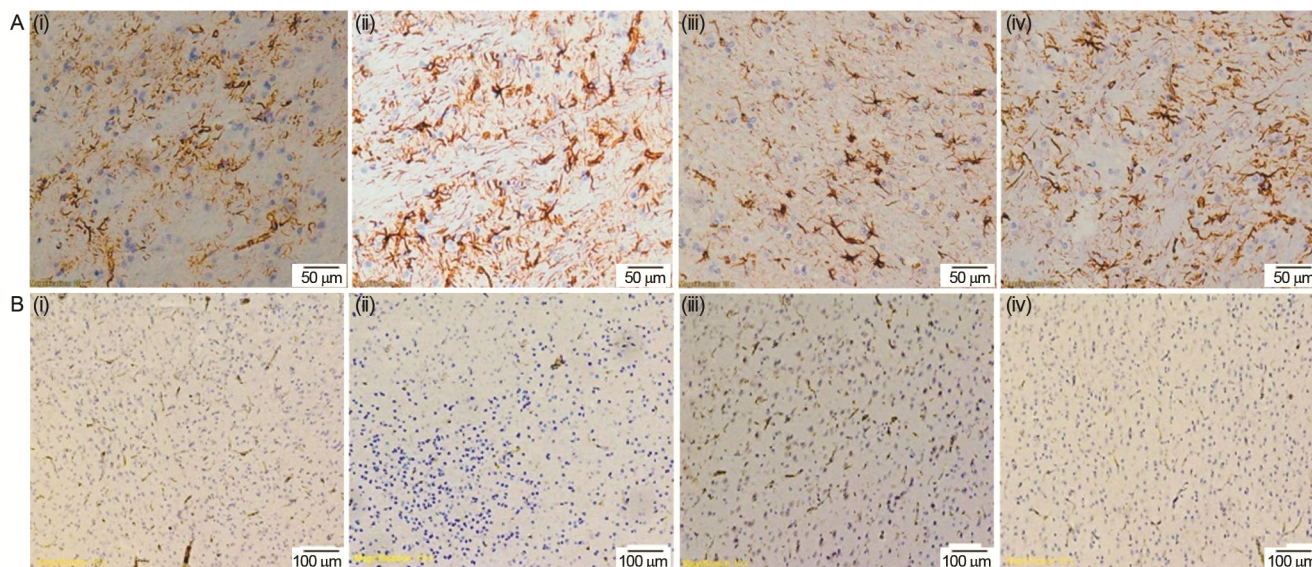


Fig. 4 — Brain sections showing immunoreactivity in all four groups. (A) Positive immunoreactivity for glial fibrillary acidic protein (GFAP) in Gr. I & III, marked increase in expression of GFAP in Gr. II and moderate increase in expression of GFAP in Gr. IV in cerebral cortex; and (B) Intense strong positive immunoreactivity for Bcl-2 protein in Gr. I & III, marked reduction in immunostaining for Bcl-2 protein in Gr. II and moderate reduction in immunostaining for Bcl-2 protein in Gr. IV in cerebral cortex.

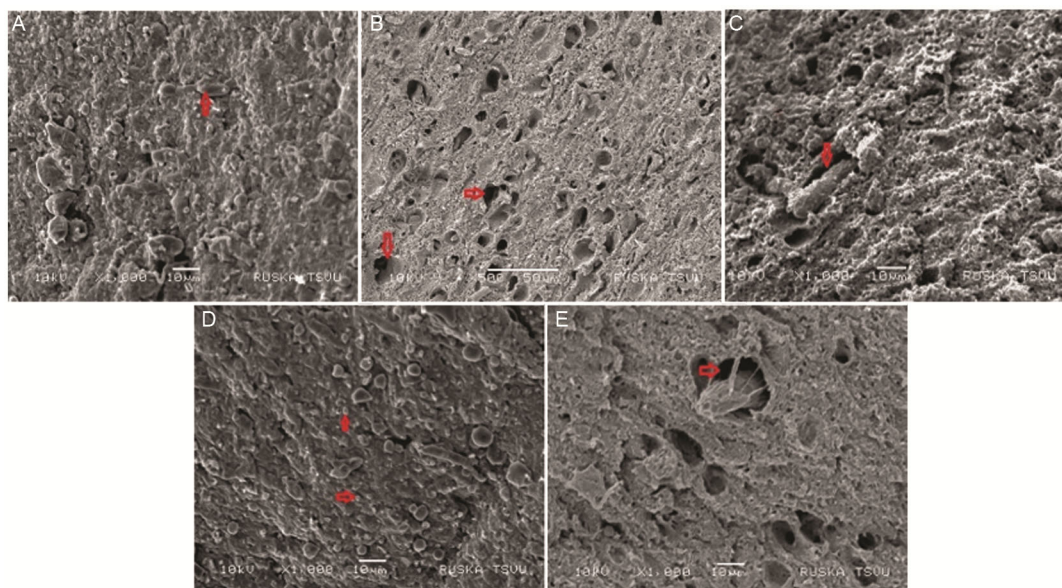


Fig. 5 — Scanning electron micrograph of brain (A-E) showing (A) moderate degeneration of neurons (arrow), (B) moderate dilation of capillaries (arrow), (C) moderate increase in perineural space (arrow) and dilation of capillaries (Gr. II, Day 16); (D) severe degeneration of neurons with shrunken nerve cell bodies (arrow) and (E) severe increase in perineural space (arrow) and dilation of capillaries (Gr. II, Day 31).

Ultrastructural pathology

SEM examination of brain of Gr. II rats on 16th day of experiment showed moderate degeneration of neurons, moderate dilation of capillaries and increase in perineural space. On 31st day, severe degeneration of neurons with shrunken nerve cell bodies, severe increase in perineural space and dilation of capillaries [Fig. 5 (A-E)] were observed. In Gr. IV rats, brain

revealed mild degeneration of neurons on 16th day of experiment. Mild dilation of capillaries and mild increase in perineural space were noticed on 31st day (Fig. 6(a-c)).

In TEM examination, moderate degeneration of neurons with swollen nucleus, clumping and margination of chromatin and round electron dense mitochondria were noticed in brain of Gr. II rats on




Fig. 6 — (A-C): Scanning electron micrograph of brain showing a. mild degeneration of neurons (arrow) (Gr. IV, Day 16); b. mild dilation of capillaries (arrow), c. mild increase in perineural space (arrow) and dilation of capillaries (Gr. IV, Day 31).

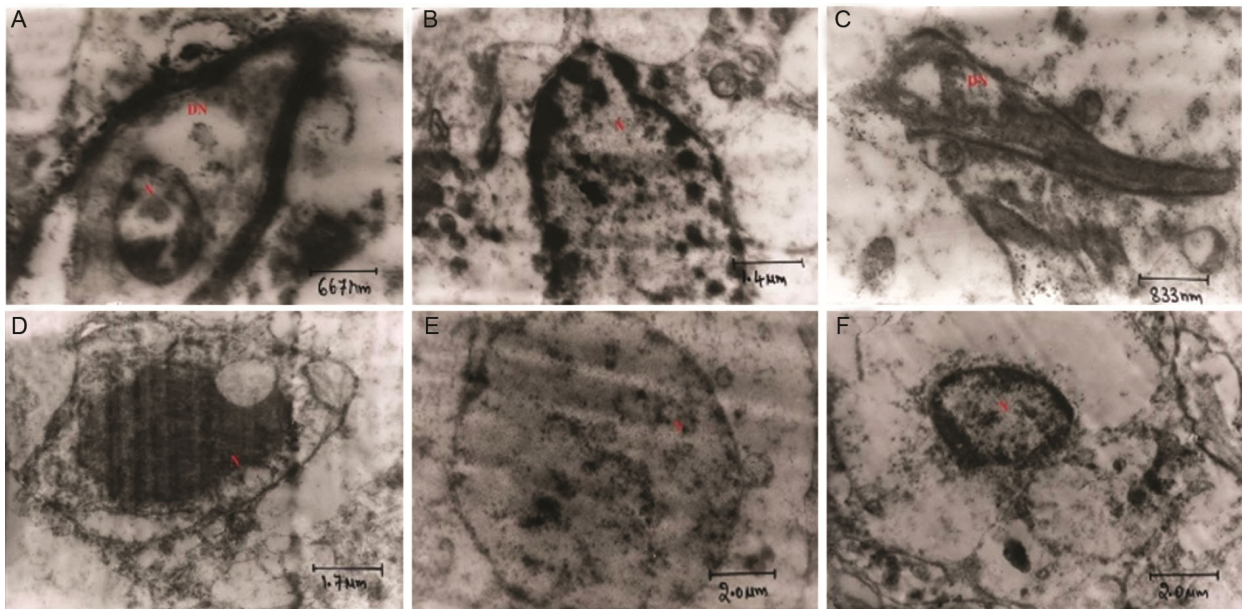


Fig. 7 — (A-F): Transmission electron micrograph of brain showing (A) moderate degeneration of neuron (DN) with swollen nucleus (N) and clumping of chromatin UA & LC 28950x, (B) moderate degeneration of neuron with swollen nucleus (N), margination of chromatin and round electron dense mitochondria UA & LC 13510x (Gr. II, Day 16); (C) severe degeneration of neuron (DN) with indistinct cytoplasmic organelles and deformed myelin sheath UA & LC 23160x, (D) severe degeneration of neuron with pyknotic nucleus (N) and cytoplasmic vacuolation UA & LC 11580x (Gr. II, Day 31); (E) mild degeneration of neuron with swollen nucleus (N) and disruption of chromatin UA & LC 9650x (Gr. IV, Day 16); and (F) mild degeneration of neuron with swollen nucleus (N), margination of chromatin and vesicular cytoplasm UA & LC 9650x (Gr. IV, Day 31).

16th day of experiment. On 31st day, severe degeneration of neurons with indistinct cytoplasmic organelles and deformed myelin sheath were observed. Few ultra thin sections revealed pyknotic nucleus and cytoplasmic vacuolation. In Gr. IV rats, brain revealed mild degeneration of neurons with swollen nucleus and disruption of chromatin on 16th day of experiment. Similar changes were also noticed on 31st day. In addition, margination of chromatin and vesicular cytoplasm [Fig. 7 (A-F)] were also observed.

Discussion

In the present study, the GSH levels in brain were significantly ($P < 0.05$) reduced in Gr. II rats when compared to Gr. I rats on 16th and 31st day of experiment. These observations are in accordance with the earlier findings¹². Similarly reduction of GSH levels in liver and kidney due to imidacloprid induced toxicity has been reported already¹³. These results are suggestive of oxidative stress induced by IMI. The decreased GSH levels may be associated with excess production of ROS released from damaged

mitochondria. The ROS might have enhanced the lipid peroxidation of cell membranes and led to increased consumption of GSH for detoxification of peroxides, thereby led to exhaustion of the GSH stores in brain of Gr. II rats. In Gr. IV rats, brain showed a significant ($P < 0.05$) increase in GSH levels in comparison with Gr. II rats on 16th and 31st day of experiment. The *W. somnifera* might have interfered in restoration of GSH levels in Gr. IV rats due to neutralization of ROS. Hypothetically, there are two reasons for restoration of GSH, first reason could be due to decrease in GSH degradation and second reason might be due to increased biosynthesis of GSH by transcriptional induction of genes responsible for GSH synthesis. This hypothesis is supported by the observations of in liver tissue of IMI induced layer birds¹⁴.

A significant ($P < 0.05$) reduction in SOD activity in brain was recorded in toxic group rats when compared to control group rats on 16th and 31st day of experiment in alignment with the earlier findings in brain^{15,16}. The reduction in SOD activity in present study might be due to the excess production of superoxide radicles by IMI resulted in increased utilization of SOD in conversion of superoxide radicles to hydrogen peroxide, led to depletion of SOD and oxidative damage to brain tissue in Gr. II rats. SOD activity was significantly ($P < 0.05$) increased in brain of Gr. IV rats in comparison with Gr. II rats on 16th and 31st day of experiment. This might be a consequence of antioxidant activity of *W. somnifera* that might have terminated the free radical chain reaction.

Significantly ($P < 0.05$) increased TBARS levels in brain were recorded in Gr. II rats when compared with Gr. I rats on 16th and 31st day of experiment. These results are in accordance with earlier reports^{17,18}. The increased TBARS levels suggests the excessive ROS production by IMI and its interaction with cell membranes led to enhanced peroxidation of poly unsaturated fatty acids (PUFA) in cell membrane which can be measured by using MDA¹⁹. The increased MDA levels may also be a consequence of depletion of GSH and SOD levels, because the main defense to alleviate oxidative stress and repair the damaged macromolecules in the cells is by enzymatic (SOD) and non-enzymatic antioxidants (GSH), which are involved in scavenging of the ROS²⁰. In present study, the GSH and SOD levels were significantly decreased in brain of Gr. II rats which led to a

significant increase in TBARS levels in IMI treated rats. The TBARS levels in were significantly ($P < 0.05$) decreased in Gr. IV rats when compared with Gr. II rats on 16th and 31st day of experiment. This might be due to antiradical and antioxidant properties of *W. somnifera* due to the presence of alkaloids and steroidal lactones which are potent free radical scavengers. Similarly, the decreased levels of TBARS in liver due to *W. somnifera* administration were noticed against the IMI induced toxicity in layer chicken¹³.

Histopathological findings in brain tissue in current experiment are in agreement with similar studies in rats²¹⁻²³. Similar observations were also documented in chicken²⁴. These changes might be due to accumulation of imidacloprid and its metabolites in the brain²⁵ which exerted toxic effect on neurons by production of ROS and brain is highly vulnerable to oxidative stress because of its lipid rich content and high oxygen consumption²⁶. The neuronal cell membrane phospholipids might have peroxidized, protein degraded, DNA damaged by ROS resulted in degeneration and necrosis of neurons. It may also be due to reduced blood supply to nervous tissue as a result of capillary damage produced by IMI. These findings are supported by elevated lipid peroxidation (TBARS) and reduced antioxidants (GSH and SOD) in brain of Gr. II rats. Minimal degree of lesions were observed in brain sections of Gr. IV rats than the Gr. II rats. It might be due to the antioxidant and rejuvenating property of WS that maintained the cellular integrity of neurons. Similar observations were noticed in rats²⁷.

In current experiment, the brain sections from Gr. II rats revealed marked increase in staining intensity of GFAP in cerebral cortex. These findings are in accordance with the findings of^{24,28}. The increased GFAP accumulation could be attributed to reactive gliosis in response to neuronal degeneration induced by IMI. These observations are supported by histopathological and ultrastructural changes in brain of IMI treated rats. In Gr. IV, the brain sections showed significant abatement in staining intensity of GFAP in cerebral cortex in comparison to Gr. II rats. It might be due to prevention of neuronal damage to certain extent by *W. somnifera* due to its antioxidant property.

Sections of brain from Gr. II rats showed marked reduction in immunostaining for Bcl-2 protein in cerebral cortex when compared to Gr. I rats. These

results reflecting the increased apoptosis process due to IMI. The brain sections from Gr. IV rats revealed mild increase in immunostaining for Bcl-2 protein in comparison to Gr. II. This is indication of *W. somnifera* antiapoptotism in brain tissue of Gr. IV rats.

In Gr. II rats, the ultrastructural changes in brain could be due to the IMI induced oxidative stress which led to neuronal degeneration as evidenced by marked increase in GFAP and decrease in Bcl2 immunostaining, significant reduction in antioxidant parameters (GSH and SOD), significant elevation in TBARS levels and histopathological lesions in brain of IMI treated rats in the present experiment. Gr. IV rats brain revealed mild ultrastructural changes. These are attributed to the toxic effect of IMI despite of the free radical scavenging activity of *W. somnifera*²⁹.

Conclusion

The results demonstrated marked histopathological, immunohistochemical and ultrastructural changes in the brain tissue of female Wistar rats due to exposure to the neonicotinoid insecticide, imidacloprid (IMI). It could be due to IMI induced oxidative stress. The co-administration of the Ashwagandha or Indian ginseng, *Withania somnifera* @ 1g/kg feed along with the IMI revealed mild to moderate improvement in all the above parameters. These findings reveal potential moderate protection against the toxic effects of IMI by Ashwagandha.

References

- Matsuda K, Shimomura M, Ihara M, Akamatsu M & Sattelle DB, Neonicotinoids show selective and diverse actions on their nicotinic receptor targets: Electrophysiology, molecular biology and receptor modeling studies. *Biosci Biotechnol Biochem*, 69 (2005) 1442.
- Girdhari LG & Rana AC, *Withania somnifera* (Ashwagandha): A Review. *Pharmacogn Rev*, 1 (2007) 129.
- Taranjeet K & Gurcharan K, *Withania somnifera* as a potential candidate to ameliorate high fat diet-induced anxiety and neuroinflammation. *J Neuroinflammation*, 14 (2017) 1.
- Feinstein RE, *Postmortem procedures in Handbook of Laboratory Animal Science*. (In: Svendsen P & Hau J, CRC Press, London, New York, Washington D.C) 2000, 383.
- Moron MS, Depierre JW & Mannervik, B, Levels of glutathione, glutathione reductase and glutathione S transferase in rat lung and liver. *Biochim Biophys Acta Gen Subj*, 582 (1979) 67.
- Balasubramanian KA, Manohar M & Mathan VI, An unidentified inhibitor of lipid peroxidation in intestinal mucosa. *Biochem Biophys Acta (BBA)*, 962 (1988) 51.
- Madhesh M & Balasubramanian KA, Microtiter plate assay for superoxide dismutase using MTT reduction by superoxide. *Indian J Biochem Biophys*, 35 (1998) 184.
- Luna GLHT, *Manual of histological and special staining techniques*. 2nd edn. (Inc. New York, Toronto London: The Blakistone Divison McGraw-Hill Book Company), 1968, 1 and 9.
- Van Noorden S, *Principles of immunostaining. Histochemistry in pathology*. 2nd edn. (Edinburgh: Churchill Livingstone), 1990, 31.
- Hsu SM, Raine L & Fanger H, Use of biotin-avidin peroxidase complex (ABP) in immuno peroxidase technique: a comparison between ABC and unlabeled antibody (PAP) procedures. *J Histochem Cytochem*, 29 (1981) 577.
- Snedecor GW & Cochran G, *Statistical Methods*, 8th edn. (Amer, IOWA, USA: IOWA State University Press), 1994.
- Duzguner V & Erdogan S, Acute oxidant and inflammatory effects of imidacloprid on the mammalian central nervous system and liver in rats. *Pestic Biochem Phys*, 97 (2010) 13.
- Soujanya S, Lakshman M, Anaad KA & Gopala Reddy A, Evaluation of the protective role of vitamin C in imidacloprid induced hepatotoxicity in male Albino rats. *J Nat Sci Biol Med*, 4 (2013) 63.
- Babu SN, Kumar AA, Reddy GA, Amaravathi P & Hemanth I, Chronic experimental feeding of imidacloprid induced oxidative stress and amelioration with vitamin C & *Withania somnifera* in layer birds. *Int J Sci Environ Technol*, 3 (2014) 1679.
- Kapoor U, Srivastava MK, Bhardwaj S & Srivastava LP, Effect of imidacloprid on antioxidant enzymes and lipid peroxidation in female rats to derive it's no observed effect (NOEL). *J Toxicol Sci*, 35 (2010) 577.
- Abdelhafez HEDH, Hammam FM, El-Dahshan AA, AboDaham H & Guo J, Imidacloprid Induces Neurotoxicity in Albino Male Rats by Inhibiting Acetylcholinesterase Activity, Altering Antioxidant Status, and Primary DNA Damage. *J Toxicol*, 2023 (2023) 1.
- Eman IH, Marwa YI, Neven HH, Marwa AI, Iten MF, Sherif AF & Sally M, Potential Mechanisms of Imidacloprid-Induced Neurotoxicity in Adult Rats with Attempts on Protection Using *Origanum majorana* L. Oil/Extract: *In Vivo* and *In Silico* Studies. *ACS Omega*, 8 (2023) 18491.
- Rajat M, Satyam S, Sanjiv S & Ravichandiran V, The neuroprotective effect of ascorbic acid against imidacloprid induced neurotoxicity and the role of HO-1 in mice. *Front Neurol*, 14 (2023) 1.
- Tsikas D, Assessment of lipid peroxidation by measuring malondialdehyde (MDA) and relatives in biological samples: Analytical and biological challenges. *Anal Biochem*, 524 (2017) 13.
- Birben E, Sahiner UM, Sackesen C, Erzurum S & Kalayci O, Oxidative stress and antioxidant defense. *World Allergy Organ J*, 5 (2012) 9.
- Bhardwaj S, Srivastava MK, Upasana K & Srivastava LP, A 90 days oral toxicity of imidacloprid in female rats: morphological, biochemical & histopathological evaluation. *Food chem toxicol*, 48 (2010) 1185.
- Vohra P & Khera KS, A three generation study with effect of imidacloprid in rats: biochemical and histopathological investigation. *Toxicol Int*, 22 (2015) 119.
- Mohit N, Bhaskar JD & Sanjiv S, Alpha-Lipoic acid alleviates imidacloprid-induced neuro-behavioral deficits in

- rats via Nrf2/HO-1 pathway, *Toxicol Mech Methods*, 34 (2024) 176.
- 24 Singh V, Hussein M, Yadav B, Singh AK, Hassan MA & Fatima N, Immunohistochemical changes in cerebral cortex of chick embryos after exposure to neonicotinoid insecticide imidacloprid. *Int J Nat Sci*, 6 (2015) 452.
- 25 Chao SL & Casida JE, Interaction of imidacloprid metabolites and analogues with the nicotinic acetylcholine receptor of mouse brain in relation to toxicity. *Pestic Biochem Phys*, 58 (1997) 77.
- 26 Salim S, Oxidative stress and the central nervous system. *J Pharmacol Exp Ther*, 360 (2017) 201.
- 27 Heba MAK, Hesham AE, Riham AE, Asmaa KA, Marwa H, Azza MT & Walaa HE, Ashwagandha (*Withania somnifera*) root extract attenuates hepatic and cognitive deficits in thioacetamide-induced rat model of hepatic encephalopathy via induction of Nrf2/HO-1 and mitigation of NF- κ B/ MAPK signaling pathways, *J Ethnopharmacol*, 277 (2021) 114141.
- 28 Abou-Donia MB, Goldstein LB, Bullman S, Tu T, Khan WA, Dechkovskaia AM & Abdel-Rahman AA, Imidacloprid induces neurobehavioral deficits and increases expression of glial fibrillary acidic protein in the motor cortex and hippocampus in offspring rats following in utero exposure. *J Toxicol Environ Health Part A*, 71 (2008) 119.
- 29 Smitha SV, Senthilkumar S & Vijayakumar J, *Withania somnifera* ameliorates nandrolone-decanoate-induced brain damage in rats by inhibiting cell death, prodynorphin mRNA expression and acetylcholinesterase activity. *Indian J Tradit Knowl*, 20 (2021) 685.